

A THESIS
FOR THE DEGREE OF MASTER OF SCIENCE

**Gonadal Sex Differentiation of
Hatchery-Reared Longtooth Grouper
(*Epinephelus bruneus*)**

Pham, Ngoc Sao

Department of Marine Life Science
GRADUATE SCHOOL
JEJU NATIONAL UNIVERSITY

2009. 12

**Gonadal Sex Differentiation of Hatchery-Reared
Longtooth Grouper (*Epinephelus bruneus*)**


Pham, Ngoc Sao

(Supervised by Professor Young-Don Lee)

A thesis submitted in partial fulfillment of the requirement for
the degree of Master of Science

2009. 12.


This thesis has been examined and approved



Thesis director, Choon-Bok Song, Professor of Jeju National University



In-Kyu Yeo, Associate Professor of Jeju National University



Young-Don Lee, Professor of Jeju National University

December 2009

.....
Date

Department of Marine Life Science
GRADUATE SCHOOL
JEJU NATIONAL UNIVERSITY

CONTENTS

ABSTRACT	i
LIST OF FIGURES	iii
LIST OF TABLES	v
I. INTRODUCTION	1
II. MATERIALS AND METHODS	4
2.1. Fish.....	4
2.2. Fish collection for determine sex differentiation.....	4
2.3. Histological study.....	5
2.4. Gonadal classification and sexual definition.....	6
2.5. Masculinization of juvenile Longtooth grouper during gonadogenesis by androgen treatment.....	6
2.5.1. 17 α - methyltestosterone treatment.....	6
2.5.2. Sampling procedure.....	7
III. RESULTS	8
3.1 Biological parameters.....	8
3.2 Gonadal differentiation and development	10
3.2.1 Undifferentiated gonad phase	10
3.2.2 Differentiation phase.....	15
3.2.3 Ovarian gonad phase.....	17
3.3. Masculinization of juvenile Longtooth grouper during gonadogenesis by androgen treatment.....	25

IV. DISCUSSION	29
V. CONCLUSIONS	34
VI. REFERENCES	35
ACKNOWLEDGEMENTS	43



ABSTRACT

This study was investigated the gonad development of the longtooth grouper (*Epinephelus bruneus*) from 1 to 365 days after hatching (DAH). Fertilized eggs were obtained from Marine and Environmental Research Institute, Cheju National University. Fish were sampled for histological analyses every five days from 1 to 50 DAH and then randomly until 365 DAH. The migrating primordial germ cells were first appeared in the area on the dorsal side of the intestine at 10 to 15 days after hatching (DAH). A diameter of the primordial germ cells ranged from 11.7 to 25.2 μm^2 at 10 and 15 DAH. The primordial gonad (PG) was first observed in 20 to 30 DAH larvae containing only somatic cell. The gonocytes were first observed at 45 DAH. At 50 DAH, the primordial gonad containing germ cells was surrounded by somatic cells and gonad remained undifferentiated. The initial ovarian cavity which was indicated by the presence of two elongated aggregations of somatic cells in the gonad at 60 DAH and then increased in size at 90 DAH. The ovarian cavity was formed at 110 DAH with large space. The oogonia were first observed in the edge of ovarian cavity of gonad at 140 DAH with average size was $13.3 \pm 2.0 \mu\text{m}$ in diameter. Primary-growth stage oocytes were observed in different lobules along of ovarian cavity at 270 DAH. The size of there primary-growth stage oocytes was $12.5 \pm 4.7 \mu\text{m}$ in diameter. The present observations indicates that ovarian differentiation associated with gonadal morphological begins at approximately 60 DAH and the gonads differentiate directly into ovaries in all

experimental fish. 17α -methyltestosterone dose tested in this study could not induced masculinization of Longtooth grouper during gonadogenesis. The most effective period for sex reversal using androgen hormone treatment in Longtooth grouper (*E. bruneus*) could be at 50 DAH before formation of ovarian cavity.



LIST OF FIGURES

Fig. 1. The growth of total length and weight of Longtooth grouper (<i>Epinephelus bruneus</i>) in indoor rearing condition.....	9
Fig. 2. Gonads of larvae Longtooth grouper (<i>Epinephelus bruneus</i>) at 10 to 20 DAH.....	11
Fig. 3. Gonadal development of Longtooth grouper (<i>Epinephelus bruneus</i>) at 25 to 40 DAH	13
Fig. 4. Gonadal development of Longtooth grouper (<i>Epinephelus bruneus</i>) at 45 to 50 DAH	14
Fig. 5. Gonadal development of Longtooth grouper (<i>Epinephelus bruneus</i>) at 60 to 100 DAH0.....	16
Fig. 6. Gonad development (oogenesis) of Longtooth grouper (<i>Epinephelus bruneus</i>) at 140 to 270 DAH.....	18
Fig. 7. Gonad development of Longtooth grouper (<i>Epinephelus bruneus</i>) at 300 to 365 DAH	19
Fig. 8. Change of gonad surface area of Longtooth grouper (<i>Epinephelus bruneus</i>) during the experimental period.....	20
Fig. 9. Schematic figure of ovarian differentiation of Longtooth grouper (<i>Epinephelus bruneus</i>) in indoor rearing condition	21

Fig. 10. Gonadal development of control and experimental group after 2 months

MT treated (180 DAH) 27

Fig. 11. Gonadal development of control and experimental group after 12

months MT treated (500 DAH)..... 28



LIST OF TABLES

Table 1. Gonadal classification and sexual definition of Longtooth grouper according to gonadal morphology present (+) and absent (-).....	6
Table 2. Summary of observation on gonad development during sex differentiation of Longtooth grouper (<i>E. bruneus</i>) at 15 to 60 DAH.....	22
Table 3. Summary of observation on gonad development during sex differentiation of Longtooth grouper (<i>E. bruneus</i>) at 90 to 365 DAH	23
Table 4. An overview of the size and growth performance of Longtooth grouper during the experimental period.....	24
Table 5. Gonadal development of Longtooth grouper treated with MT	26

I. INTRODUCTION

The groupers are considered as luxury seafood in Asian because of their high quality flesh. Main aquaculture production of these species comes from the Indo-Pacific region (Donaldson et al., 2003). Supply of juvenile for aquaculture mainly obtains from hatcheries, in which success of artificial propagation depends upon hormonal induction of broodstock. Most grouper species are protogynous hermaphrodites, the fish first function as females and then late transform into males when they have reached a larger size (Shapiro et al., 1993; Sadovy and Colin, 1995; Bhandari et al., 2003; Yeh et al., 2003). Difference in maturation period of the females and males is considered as major constraint that delays aquaculture development of these fish species. (Yamazaki, F., 1983; Kuwamura & Nakashima, 1998; Lee et al., 2008 and Sadovy de Mitcheson and Liu, 2008). It is difficult to collect sufficient number of males from the wild or culture for artificial propagation. The testes exhibit the morphology through the sex change in most of epinephelines was an ovarian structure, with a lumen and sperm sinuses within gonadal walls (Sadovy and Colin, 1995; Liu and Sadovy, 2004; Alam and Nakamura, 2007; Erisman et al., 2008., Sadovy de Mitcheson and Liu, 2008; Liu and Sadovy de Mitcheson, 2008). This indicates that male can develop directly from juvenile or female through sex change (Liu and Sadovy, 2004; Alam and Nakamura, 2007; Sadovy and Liu, 2008; Liu and Sadovy, 2009; Murata et al., 2009a). Alam and Nakamura (2007) reported that honeycomb grouper (*Epinephelus merra*) testes including sperm duct and efferent duct were observed at the wall of the ovarian cavity, between stromal tissue and tunica ovary. The testis becomes function only

after the ovary was ceased to function (Yamamoto, 1969), however the ovarian cavity remained in the newly formed testis (Alam and Nakamura, 2007).

Longtooth grouper (*Epinephelus bruneus*), a coral-reef fish species, is recognized as one of the most commercially valued fish in Jeju island, Korea. The artificial seed production technique was investigated since 1993 (Lee et al., 2008), and mass seed production has been established since 2005 (Song et al., 2005; Oh, 2006). Studies (Sawada et al, 1999; Song et al, 2005; Oh, 2006) reported that larvae of longtooth grouper undergone 50 days for metamorphosis. Like other grouper species (sub-family Ephinaphelinae), longtooth grouper (*Epinephelus bruneus*) are protogynous hermaphrodite with a complex and socially structure reproductive behaviour (Song et al, 2005; Oh, 2006; Lee et al, 2008). The sex change from female to male begins at body size of 3-5 kg and larger number of males frequently was found at body size of 5-8 kg (Oh, 2006). Recent attempts have been done to determine sex differentiation, which can provide an important guidance for improving artificial propagation of this species.

Histological observation of gonads is important approach for precisely understanding of the mechanism of sex differentiation (Nakamura et al., 1998), and provides guidance for determining the hormone sensitive period of fish (Strüssmann et al., 1996). In general, sexually undifferentiated fish are higher sensitive to effects of steroid treatment than sexually differentiated ones (Piferrer, 2001). Recent studies have reported that fish treated with androgen and aromatase inhibitors around the time of sex differentiation can completely change their sex (Yamamoto, 1969; Devlin and Nagahama, 2002). Administration of sex steroids (e.g., testosterone: T) and their derivatives (e.g., methyltestosterone: MT), or inhibitors of steroidogenic

enzymes (e.g., fadrozole) can induce sex change in grouper species from female to male (Kuo et al., 1988; Tan-Fermin et al., 1994; Bhandari et al., 2003; Yeh et al., 2003; Bhandari et al., 2004; Sarter et al., 2006; Li et al., 2007; Hur, 2008). Hence, androgen hormones are administrated by different methods, such as oral administration, injection and implantation, and with different doses (Yeh et al., 2003). For instance, 17 α - methyltestosterone (MT) has been commonly used, but the dose applied has varied among various studies for groupers. Kuo et al. (1988) successfully induced sex change of *E. tario* by oral administration of MT at daily dose of 0.5 mg MT kg⁻¹ body weight for 5 months. Injection of 0.5 mg MT kg⁻¹ body weight was reported to induce masculinization of *E. septemfasciatus* (Song, 2004), whereas, masculinization of *E. bruneus* was succeeded by implantation of 2 mg MT kg⁻¹ body weight (Oh, 2006). Most masculinization studies have been conducted for groupers belonging to the genus *Epinephelus* in mature female, except for *E. marginatus* and *E. malabaricus*, in which sex reversal was performed in 1-year-old juvenile using MT (Glamuzina et al., 1998; Sarter et al., 2006) and under-yearling juvenile (Murata et al., 2009b). There is no report of masculinization of juvenile Longtooth grouper during gonadogenesis.

The aims of this study were; (1) to investigate the timing of sex differentiation and gonadal development of Longtooth grouper larvae and juvenile, and (2) determine masculinization of fish by androgen administration.

II. MATERIALS AND METHODS

2.1. Fish

Larvae from 1 to 90 days after hatching (DAH) were obtained from a private hatchery in Hamdoek, Jeju, Korea and transported to Marine and Environment Research Institute, Jeju National University. From September to November, 500 fish were reared in 3000 L square tank for determine sex differentiation (un-treatment). Other 1000 fish were divided in four 250 L square tanks (250 fish per tank) for androgen treatment. Filtered seawater was continuously provided in each tank. Water exchange rate was 100% very 2 h and water temperature was ranged from 20 to 24 °C. During winter season (from December 2008 to March 2009), fish were reared in 500 L tanks in a recirculation system. Water temperature maintained at 22 °C using heaters, water flow rate was set at 10 L min⁻¹ and water was exchanged every 2 week. Fish were hand-fed twice a day with commercial pellets at a daily ration of 3% body weight.

2.2. Fish collection for histological study

Fish (from 1 to 365 DAH) were collected for gonadal histological study from June 2008 to August 2009. Fifteen to twenty fish were collected every day from day 1 to 10. Ten fish were collected every 5 days between day 10 to day 60, every 10 day from day 90 to day 140, and monthly from day 180 to day 365.

2.3. Histological study

After measuring body length and weight, larvae and juvenile were fixed in Bouin's solution for 24 h, dehydrated in a graded series ethanol and embedded in paraffin. The paraffin embedded specimens were sectioned in 3 to 5 μm thickness using a rotary microtome. Slides were stained with Hansen's hematoxylin and eosin and observed on light microscope (AX70 Shop, N7COMP 370, Carl Zeiss, Germany).

The germ cell and gonad diameters were measured to calculate of surface area. Gonad and germ cell surface area was calculated according to the equation described by Uguz (2008).

$$\text{Surface area } (\mu\text{m}^2) = (\text{width} \times \text{length} \times 3.14)/4$$

2.4. Gonadal classification and sexual definition

Gonads of fish were classified into three categories including undifferentiated-phase (UP), differentiation-phase (DP), and ovarian-phase (OP) (Table 1).

Table 1. Gonad classification and sexual differentiation in Longtooth grouper

Gonadal phase	Gonadal morphology							
	PGCs	BV	GC	OC	Og	O1	O2	SC
UP	+	+	+	-	-	-	-	-
DP	-	+	+	+	-	-	-	-
Op	-	+	+	+	+	+	+	-

For gonadal phase: UP, Undifferentiated gonad phase; DP, Differentiation phase; OP, Ovarian phase

For gonadal morphology: PGC, primordial germ cells; BV, blood vessels; GC, gonocyte; OC, ovarian cavity; Og, oogonia; O1, primary-growth stage oocyte; O2, cortical-alveolus stage oocyte; SC, spermatogenic cyst.

2.5. Masculinization of juvenile Longtooth grouper by androgen treatment

2.5.1. 17 α - methyltestosterone (MT) treatment

One thousand juvenile (90 DAH) were randomly allocated in four 250 L tanks at a density of 250 fish per tank. After two months, they were transferred to 1000 L tanks. Four experimental diets were prepared to contain 0 mg, 1 mg, 5 mg and 10 mg 17 α - methyltestosterone (MT) kg⁻¹ DM. Hormone was dissolved in pure

ethanol (99%) prior to adding into the diets. The diet containing 0 mg MT was considered as the control. The diets were air-dried overnight for evaporation of ethanol and kept at 4 °C until used. Fish were hand-fed four times per day at a daily ration of 5% body weight per day. The feeding period lasted for 30 days. After end of the treatment period, fish were fed commercial pellets without supplementation of hormone at a daily ratio 3 % body weight per day for 380 days.

2.5.2. Sampling procedure

At the beginning of the treatment, six fish were sampled for determining the gonadal status. After two months, another 5 fish from each group were sacrificed and their gonads were collected to examine the effect of MT. At the end of the feeding period (380 days), 10 fish from each treatment group and 3 fish from the control group were sacrificed to determine their sex by histological method.

III. RESULTS

3.1. Biological parameters

During undifferentiated gonad phase (from 5 days after hatching (DAH) to 50 DAH), body weight and total length of Longtooth grouper larvae ranged from 0.001 to 0.2786 g and 2.9 to 27.4 mm respectively. In initial ovarian phase (from 60 DAH to 130 DAH), body weight ranged from 0.538 to 14.908 g with the total length was 35.5 to 101.1 mm. In the ovarian gonad phase (from 140 DAH to 365 DAH), body weight and total length ranged from 16.30 to 98.47 g and 105.5 to 197.1 mm, respectively (Fig. 1)



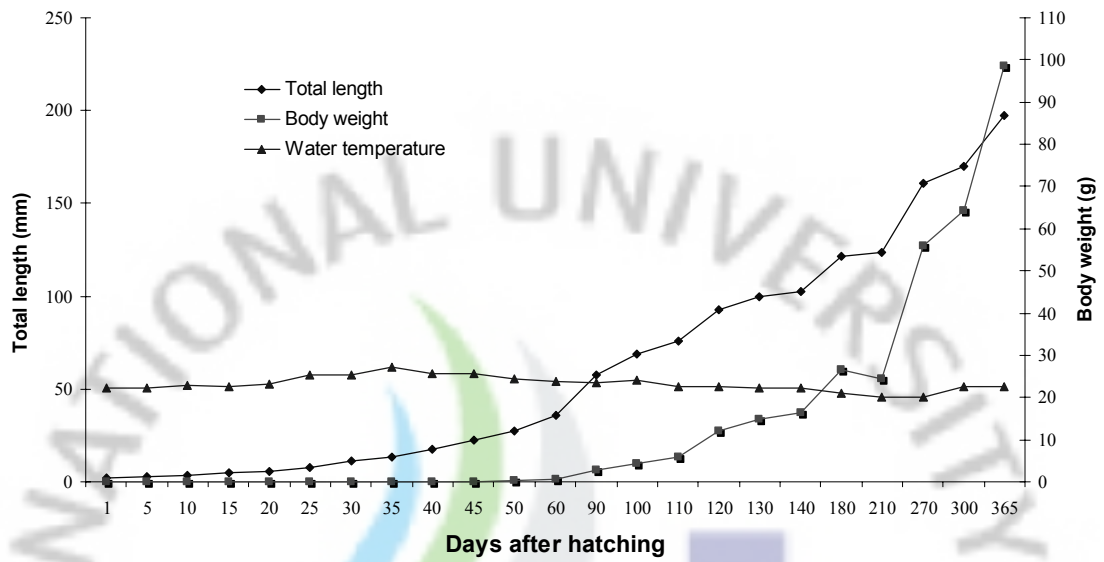


Fig. 1. The growth of total length and weight of Longtooth grouper (*Epinephelus bruneus*) in indoor rearing condition

3.2. Gonadal differentiation and development

3.2.1. Undifferentiated gonad phase

In sagittal section, the primordial germ cell (PGC) was observed throughout gut and under the mesonephric duct at 10 DAH (Fig. 2A, B). At 15 DAH, PGCs were located adjacent hindgut with a large nucleus size. At this stage, PGC was marked border between the cytoplasm and the nucleus, which was intensively stained by hematoxylin (Fig. 2C). The diameter of PGCs ranged from 11.7 to 25.2 μm^2 at 10 and 15 DAH. At 20 to 30 DAH, primordial gonad appeared below the mesonephric duct at either side of the mesentery in the posterior portion of the body cavity with a few somatic cell (Fig. 2D; 3A, B). The cross section surface area of primordial gonads at this stage ranged from 87.0 to 176.6 μm^2 (Fig. 8). The blood vessel was observed in the primordial gonads at 35 DAH (Fig. 3C). The average of primordial gonad surface at this stage was $202.4 \pm 31.4 \mu\text{m}^2$. At 40 DAH, the germ cells were distinguished from the somatic cells by their larger size. Nuclei of the germ cells were stained by hematoxylin more intensively than the cytoplasm (Fig. 3D). The primordial gonad increased in size with surface area of $357.5 \pm 123.1 \mu\text{m}^2$ (Fig. 8). At 45 DAH, the germ cells showed nuclei containing dispersed chromatin in the form of an irregular meshwork, which numerous small chromatin masses were suspended (Fig. 4A). One individual showed relatively large gonads with the surface area of 588.8 and 785.0 μm^2 while the average size was $543.8 \mu\text{m}^2$. At 50 DAH, the larvae were completed metamorphosis to become juvenile fish with average body weight and total length was 0.279 ± 0.061 g and 27.4 ± 2.4 mm, respectively. The primordial gonads were pear-shape consisting germ cells surround by somatic cells,

which characteristic were similar to observed in 40 and 45 DAH (Fig. 4B). The surface area was $744.1 \pm 227.0 \mu\text{m}^2$ (Fig. 8).



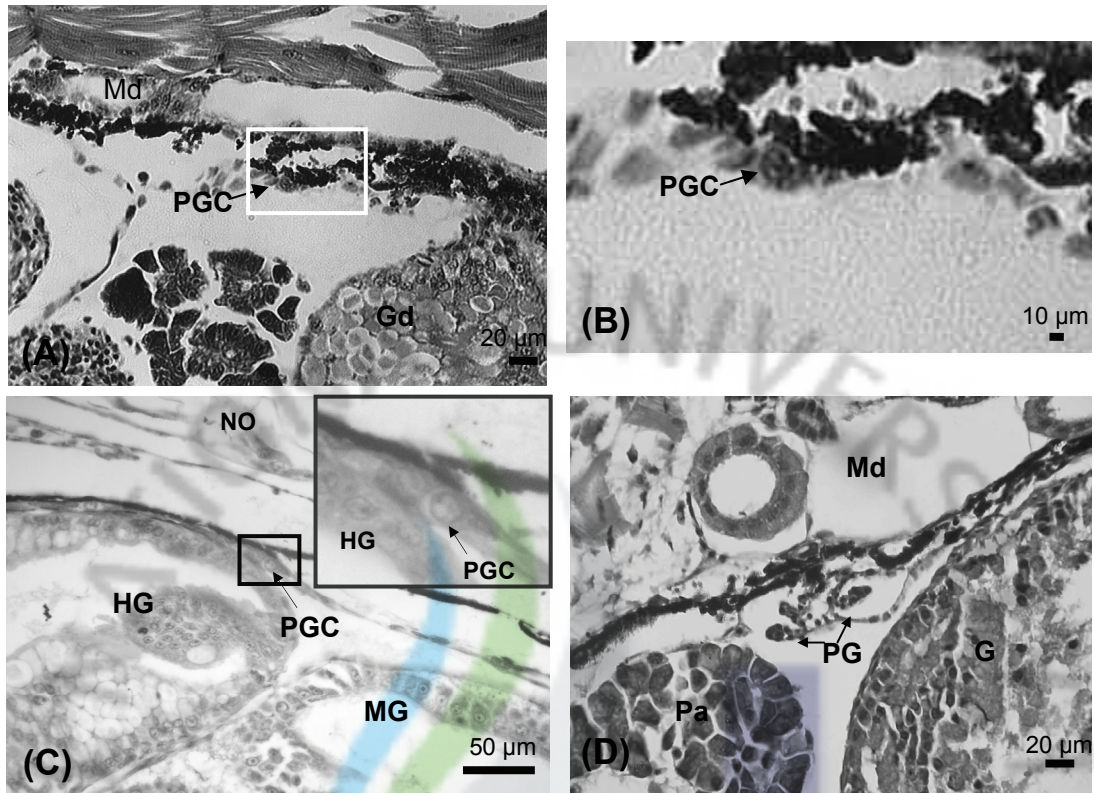


Fig. 2. Gonads of larvae Longtooth grouper (*Epinephelus bruneus*) at 10 to 20 DAH. (A). Sagittal section show primordial germ cell located between mesonephric duct and intestine at 10 day after hatching; (B). High magnification of primordial germ cell of picture A; (C). Sagittal section at 15 DAH showed primordial germ cell located at anterior part of the body cavity; (D). Cross section gonad at 20 DAH showed pair primordial gonad below mesonephric duct with a few somatic cell. G, gut; Gd, gut duct; HG, hindgut; MG, midgut; Md, mesonephric duct; NO, notochord; Pa, pancreatic; PG, primordial gonad; PGCs, primordial germ cells.

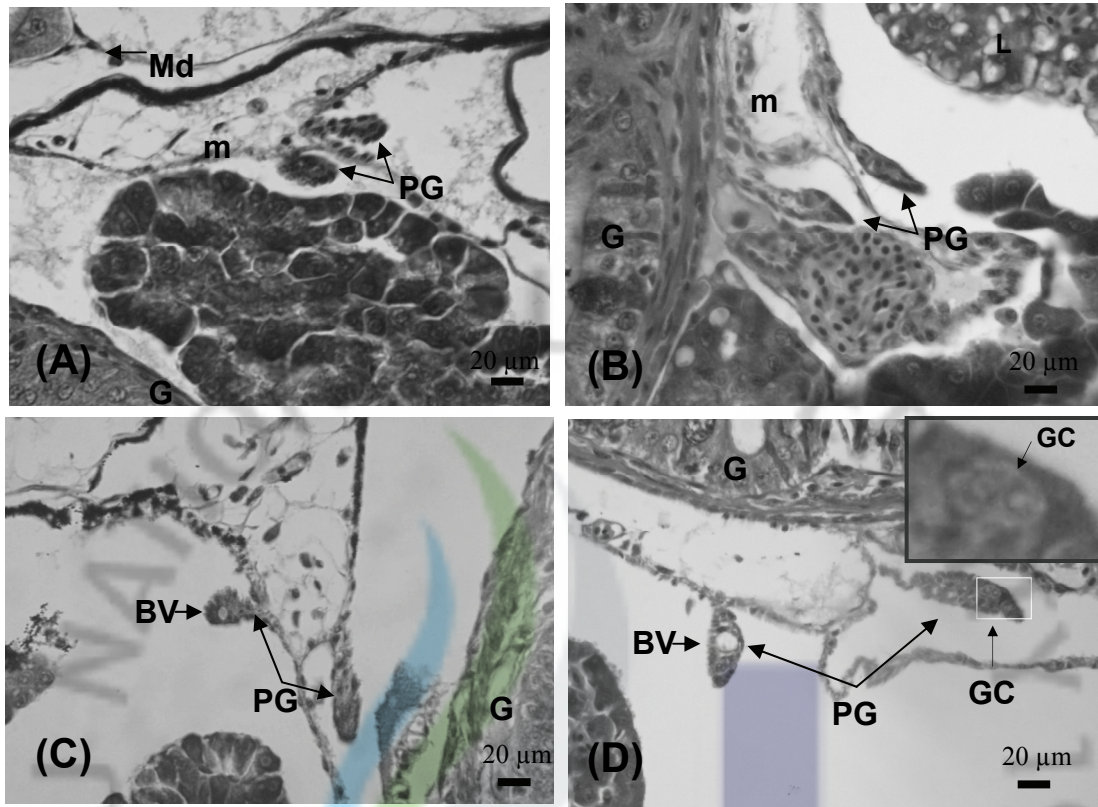


Fig. 3. Gonadal development of Longtooth grouper (*Epinephelus bruneus*) at 25 to 40 DAH; (A). Cross section gonad at 25 DAH showed primordial gonad located under mesospheric duct with somatic cells; (B). Cross section primordial gonad at 30 DAH located between liver and intestine; (C). Cross section primordial gonad at 35 DAH located adjacent gut with appeared of blood vessel; (D). Cross section gonad at 40 DAH showed primordial gonad with germ cells surround by somatic cells. BV, blood vessel; G, gut; GC, germ cell; m, mesentery; Md, mesospheric duct; PG, primordial gonad; Pa, pancreatic.

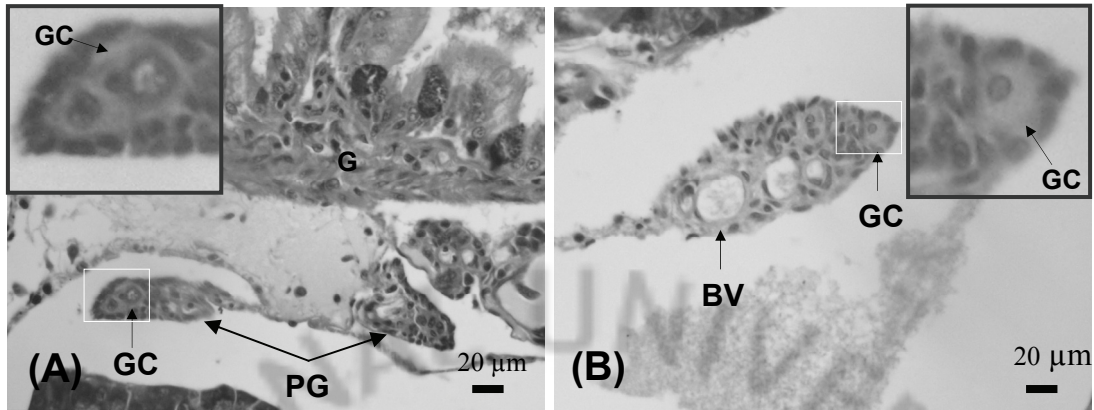


Fig. 4. Gonadal development of Longtooth grouper (*Epinephelus bruneus*) at 45 to 50 DAH. (A). Cross section with undifferentiated gonad at 45 DAH showed primordial gonad with somatic cells; (B). Undifferentiated gonad at 50 DAH with appeared of blood vessel, the germ cell distributed between somatic cells. BV, blood vessel; GC, germ cell; G, gut; PG, primordial gonad.

3.2.2. Differentiation phase

At 60 DAH, out of ten fish examined only four individual appeared to have initial ovarian cavity which was indicated by the presence of two elongated aggregations of somatic cells in the gonad (Fig. 5A). The number of somatic cells was increased and the blood vessel was immigrated in the central of gonad. The surface area of primordial gonad was $956.1 \pm 510.3 \mu\text{m}^2$ (Fig. 8). At 90 DAH, the two elongation sheets of somatic cells more developed upward and downwards to forming ovarian cavity (Fig. 5B). The gonad increased size with average of surface area was $10,126.5 \pm 3,958.3 \mu\text{m}^2$ (Fig. 8). The ovarian cavity was clearly observed with a large space in the central part of the gonad at 110 DAH (Fig. 5C). The gonad was rapidly increased in size compared with the gonads at 90 DAH which indicated by an average gonad surface area was $27,867.5 \pm 7,274.4 \mu\text{m}^2$ (Fig. 8). At 120 DAH to 130 the somatic cells continued mitosis to increase size (Fig. 8). At this stage, the gonads were exhibited morphological characteristic resembling in gonad at 110 DAH.

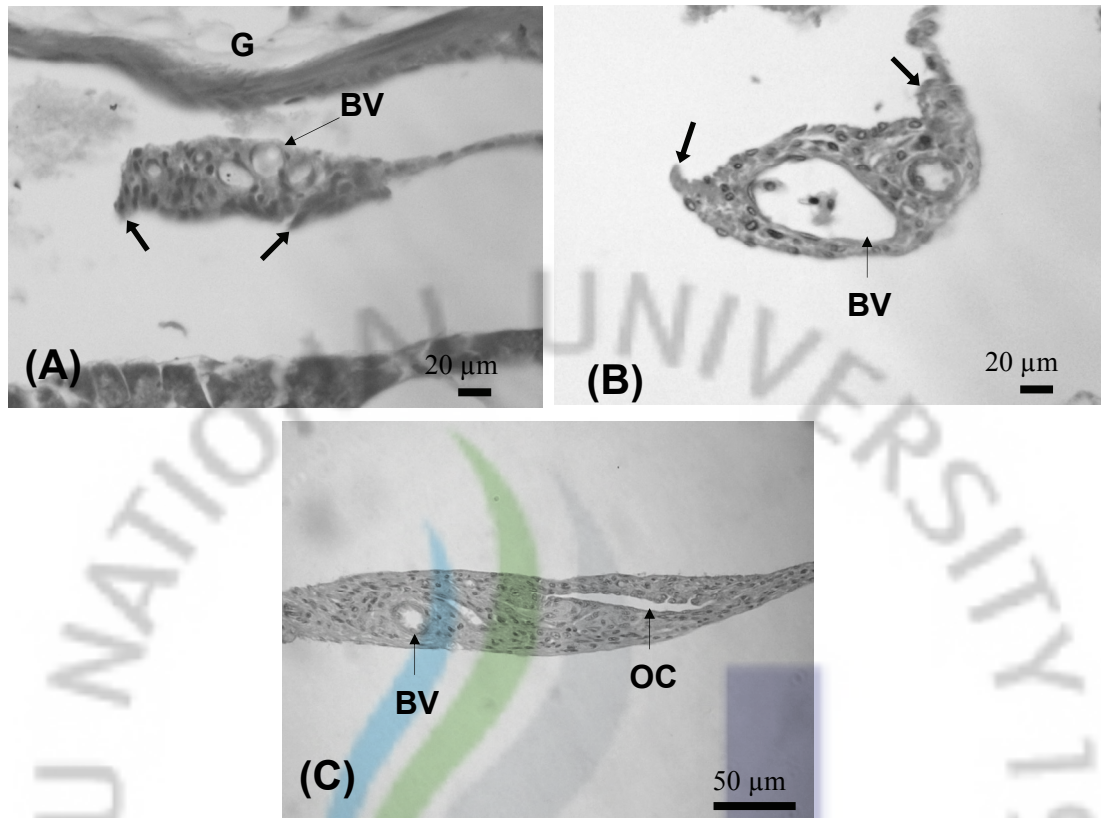


Fig. 5. Gonadal development of Longtooth grouper (*Epinephelus bruneus*) at 60 to 100 DAH. (A). Cross section gonad at 60 DAH showing two somatic elongations; (B). Cross section gonad at 90 DAH showing two somatic elongations more develop to forming the initial ovarian cavity were indicated by the thick arrows. Cross section gonad at 110 DAH show completed form of ovarian cavity; (C). BV, blood vessel; G, gut; OC, ovarian cavity

3.2.3. Ovarian gonads phase

The oogonia were first observed in the gonads of 3 individuals at 140 DAH, which indicate that gonad was entered to oogenesis. The average size of oogonia was $13.3 \pm 2.0 \mu\text{m}$ in diameter which were migrated at the edge of ovarian cavity (Fig. 6A). The number of oogonia in the ovary increased at 180 DAH and size of oogonia was $16.8 \pm 4.5 \mu\text{m}$ in diameter. The oogonia were observed in six individuals out of 9 fish (Table 3). The oogonia were enclosed by somatic cells and distributed between somatic tissues along the ovarian cavity. Some oogonia had already entered into mitosis division (Fig. 6B). At 210 DAH, seven individuals had ovaries containing oogonia which distributed along the inner periphery of the ovarian cavity (Fig. 6C). The oogonia at this stage were increased in number and diameter rang from 10.0 to 22.5 μm . At 270 DAH, a few primary-growth stage oocytes were observed in one individual (Table. 3). The primary-growth stage oocytes were resided in different lobules along of ovarian cavity (Fig. 6D). The diameter of primary-growth stage oocytes was $12.5 \pm 4.7 \mu\text{m}$. However, the primary-growth stage oocyte could not observe at this stage at all the specimen (Table 3). At 300 DAH, three individuals with ovaries containing primary-growth stage oocytes were observed (Table 3). The number of oogonia and primary-growth stage oocytes increased gradually. The diameter of oogonia was $16.3 \pm 3.2 \mu\text{m}$. At this stage the proliferation of oogonia was obvious that the ovaries entered mitosis division (Fig. 7A). At 365 DAH, six individuals had ovaries contained primary-growth stage oocyte which increased of size to average $22.1 \pm 4.9 \mu\text{m}$ in diameter. At this stage abundant of oogonia were observed (Fig. 7B). Sagittal section at 365 DAH showed that the ovary had contained only oogonia which have already underwent into mitosis division with different size.

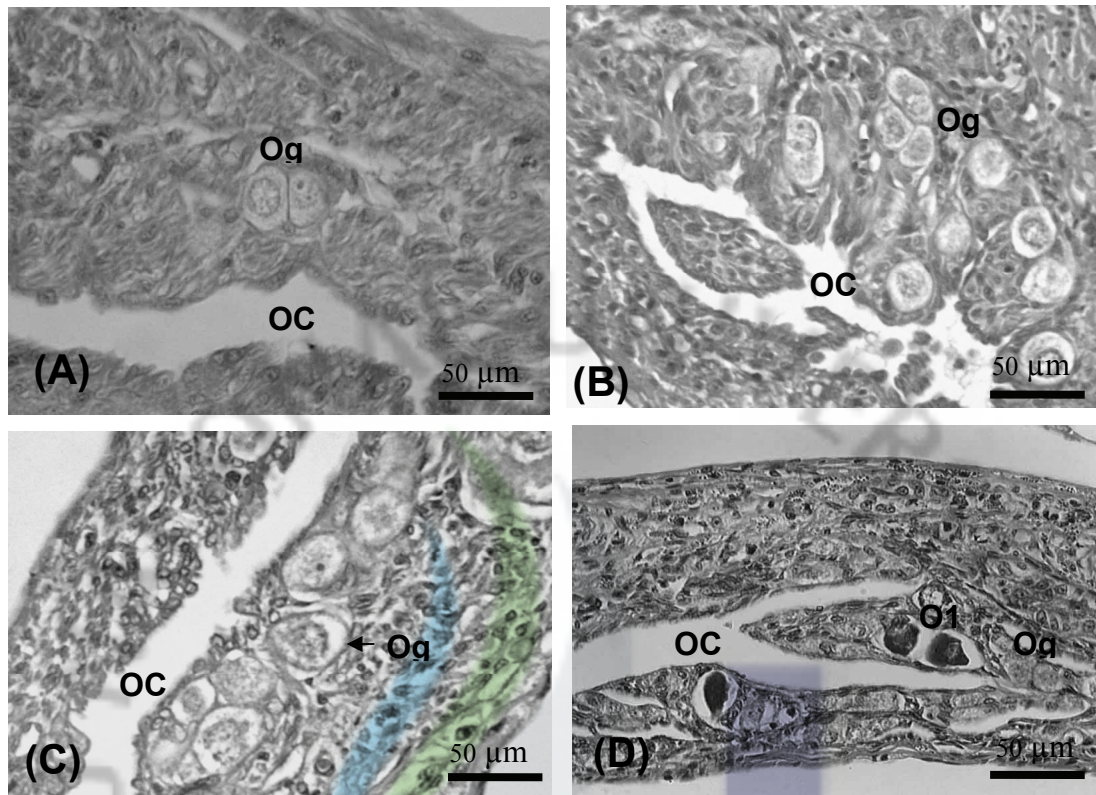


Fig. 6. Gonad development (oogenesis) of Longtooth grouper (*Epinephelus bruneus*) at 140 to 270 DAH. (A). Cross section gonad at 140 DAH show appearance of oogonia; (B). Cross section gonad at 180 DAH show oogonia were entered mitosis division; (C). Cross section gonads at 210 DAH showed oogonia immigration a long ovarian cavity; (D). Cross section gonad at 270 DAH showed a few primary-growth stage oocyte immigrate a long ovarian cavity. OC, ovarian cavity; Og, oogonia; O1, primary growth stage oocyte.

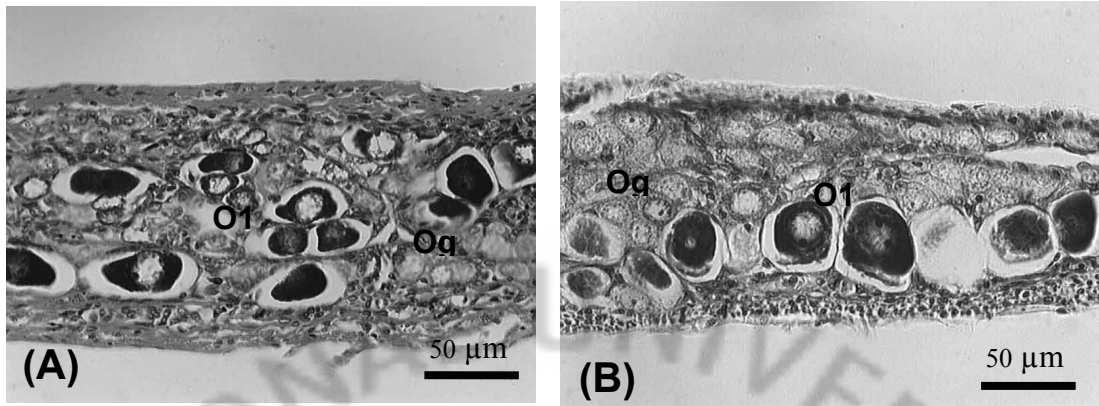


Fig. 7. Gonad development of Longtooth grouper (*Epinephelus bruneus*) at 300 to 365 DAH. (A). Cross section gonad at 300 DAH show a large number of oocytes; (B). Cross section gonad at 365 DAH showed increased size of primary-growth stage oocytes; Og, Ogonia; O1, primary growth stage oocyte.

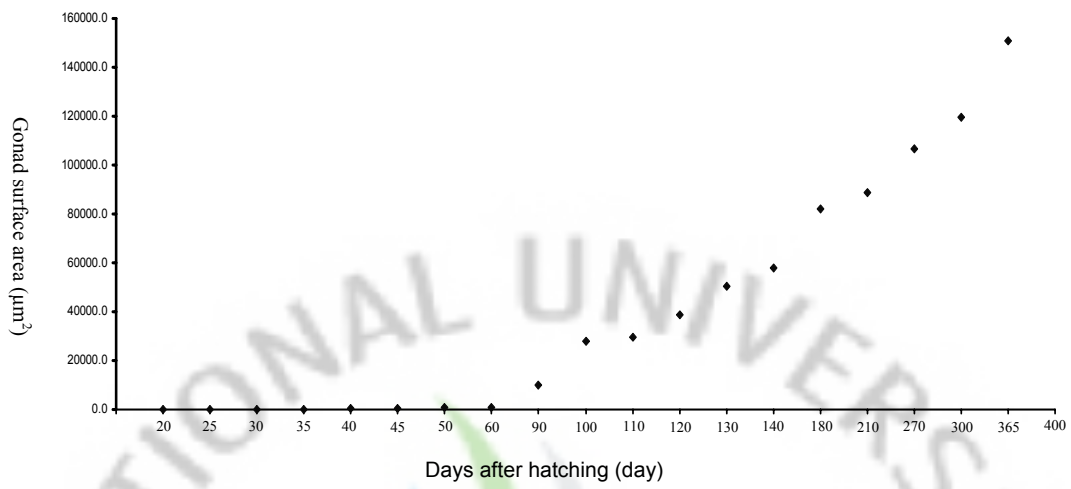


Fig. 8. Change of gonad surface area of Longtooth grouper (*Epinephelus bruneus*) during the experimental period.

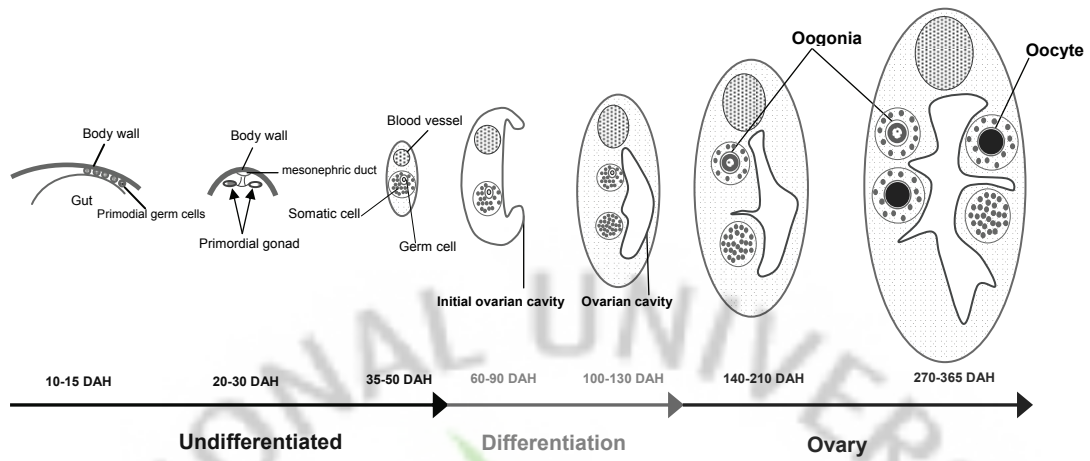


Fig. 9. Schematic figure of ovarian differentiation of Longtooth grouper (*Epinephelus bruneus*) in indoor rearing condition.

Table 2. Summary of observation on gonad development during sex differentiation of Longthroat grouper (*E. bruneus*) at 15 to 60 DAH

Age (DAH)	Body length (mm)	Sex					Histological characteristics of gonads
		U	D	Og	O	O1	
10	3.7 ± 0.5	10	-	-	-	-	PGCs were located above hindgut with a large nucleus size.
15	4.9 ± 0.3	10	-	-	-	-	PGC was marked border between the cytoplasm and the nucleus, which was intensively stained by hematoxylin
20	5.7 ± 1.0	10	-	-	-	-	The pair primordial gonads are present in the posterior region of the abdominal cavity, immediately below the mesonephric duct with a few somatic cells and the PG increased the size with age. The blood vessel was first occurred in primordial gonad at thirty five days after hatching
25	8.0 ± 0.7	10	-	-	-	-	
30	11.6 ± 1.0	10	-	-	-	-	
35	13.3 ± 1.4	10	-	-	-	-	
40	17.7 ± 2.0	10	-	-	-	-	
45	22.3 ± 1.9	10	-	-	-	-	The germ cells were appeared with a large nuclei, which were stained by hematoxylin
50	27.4 ± 2.4	10	-	-	-	-	
60	35.5 ± 3.1	6	4	-	-	-	The initial ovarian cavity formation which was indicated by the presence of two elongated aggregations of somatic cells in the gonad

Note: U, undifferentiated gonad; D, differentiated gonad; O, ovarian; Og, oogonia; O1, primary growth stage oocyte

Table 3. Summary of observation on gonad development during sex differentiation of Longthroat grouper (*E. bruneus*) at 90 to 365 DAH

Age (DAH)	Body length (mm)	Sex				Histological characteristics of gonads
		U	D	O	O1	
90	57.3 ± 6.7	2	4	-	-	Two elongation sheets of somatic cells more developed upward and downwards to forming ovarian cavity
100	69.9 ± 9.0	-	8	-	-	Ovarian cavity was completed form. Germ cell and somatic cells underwent through mitosis to increase in size of gonad
110	77.9 ± 11.6	-	8	-	-	
120	94.2 ± 12.5	-	9	-	-	
130	101.1 ± 8.4	-	7	-	-	
140	105.3 ± 12.1	-	4	3	-	The present of oogonia migrate at edge of ovarian cavity indicated that the gonad was entered to oogenesis
180	125.1 ± 12.5	-	3	6	-	The oogonia had entered into mitosis division
210	125.7 ± 12.3	-	1	7	-	The ovary appeared to have abundant of oogonia which distributed along the inner periphery of the ovarian cavity
270	160.6 ± 11.8	-	-	7	1	The ovary appeared to have a few of primary growth stage oocyte
300	170.0 ± 19.1	-	-	5	3	The ovary appeared to have primary growth stage oocyte
360	197.9 ± 19.8	-	-	4	6	

Note: U, undifferentiated gonad; D, differentiation gonad; O, ovarian; Og, oogonia; O1, primary growth stage oocyte

Table 4. An overview of the size and growth performance of Longtooth grouper during the experimental period

Period	Group	Average TL	Average BW	DAH
		(cm)	(g)	
Initial control	Initial (n=6)	5.7	2.7	90
	Control (n=5)	12.0	25.7	
2 months after treated	MT1 (n=5)	12.3	28.0	180
	MT2 (n=5)	12.3	27.2	
	MT3 (n=5)	11.6	22.4	
	Control (n=3)	20.7	127.8	
12 months after treated	MT1 (n=10)	20.1	119.1	500
	MT2 (n=10)	19.5	102.7	
	MT3 (n=10)	20.2	122.3	

MT1, 1 mg 17 α -methyltestosterone per kg diet; MT2, 5 mg 17 α -methyltestosterone per kg diet; MT3, 10 mg 17 α -methyltestosterone per kg diet; TL, total length; BW, body weight; DAH, days after hatching.

3.3. Masculinization of juvenile Longtooth grouper by androgen treatment

Table 4 show the size, age and growth of Longtooth grouper during the MT treatment period. There were no significant differences in total length and body weight of fish fed diets containing different. No male was observed in fish treated with different MT concentration (Table 5). This indicates that the MT concentration used did not effect on the sex differentiation of Longtooth grouper. The gonad of MT treated after 2 months consist of oogonia, which was similar to the gonad of fish in the control diet (Fig. 10). The gonad of MT treated fish and in the control fish after 1 year, contained abundance of oocytes (Fig. 11). No male germ cell was observed in the fish which were treated by MT (Fig. 11B, C, D)

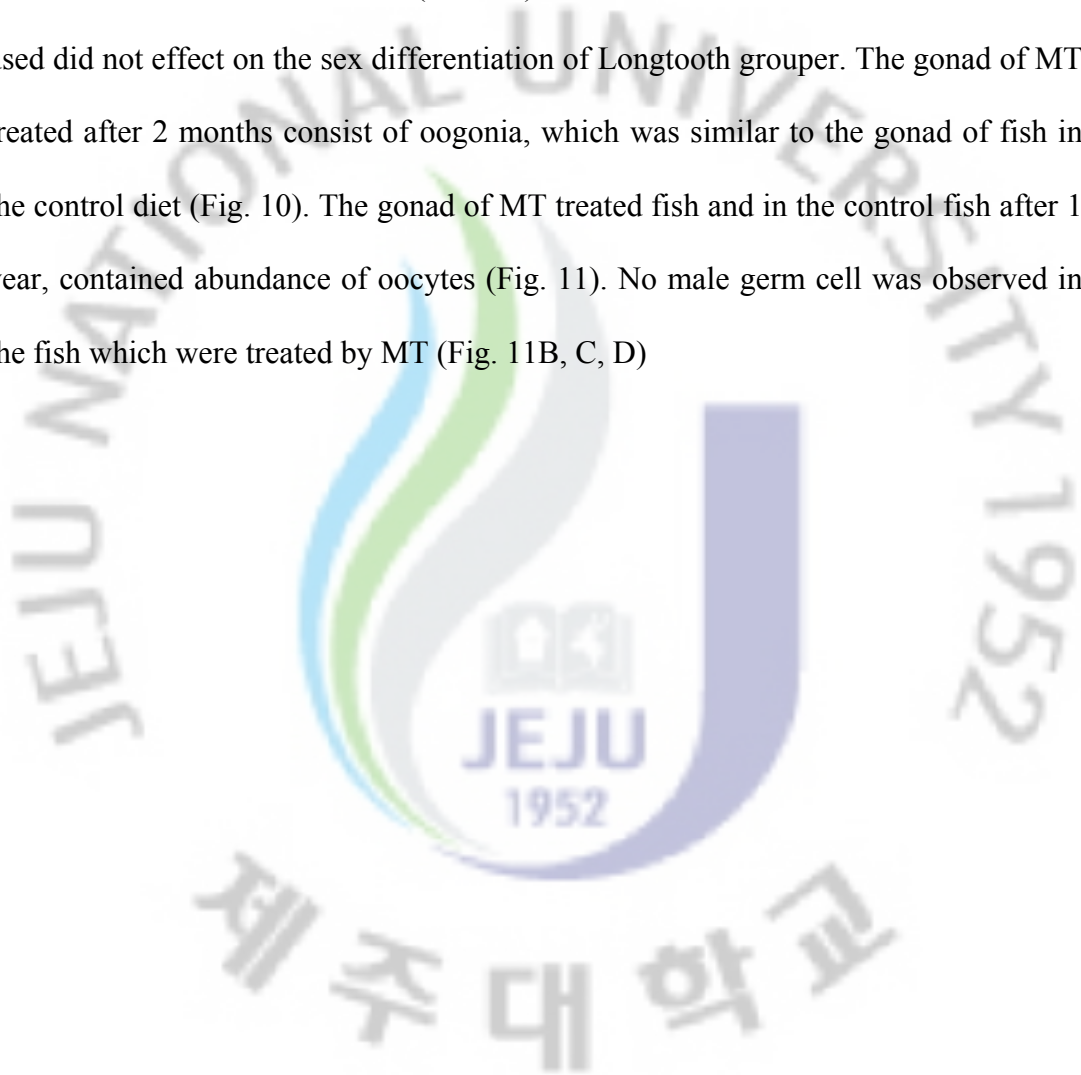


Table 5. Gonadal development of Longtooth grouper treated with MT

Period	Group	Gonadal development			Rate of male (%)
		Testis	Ovary	Unknown	
2 months after treated	Control (n=5)	0	5	0	0
	MT1 (n=5)	0	5	0	0
	MT2 (n=5)	0	5	0	0
	MT3 (n=5)	0	5	0	0
12 months after treated	Control (n=3)	0	3	0	0
	MT1 (n=10)	0	10	0	0
	MT2 (n=10)	0	10	0	0
	MT3 (n=10)	0	10	0	0

MT1, 1 mg 17 α -methyltestosterone per kg diet; MT2, 5 mg 17 α -methyltestosterone per kg diet; MT3, 10 mg 17 α -methyltestosterone per kg diet.

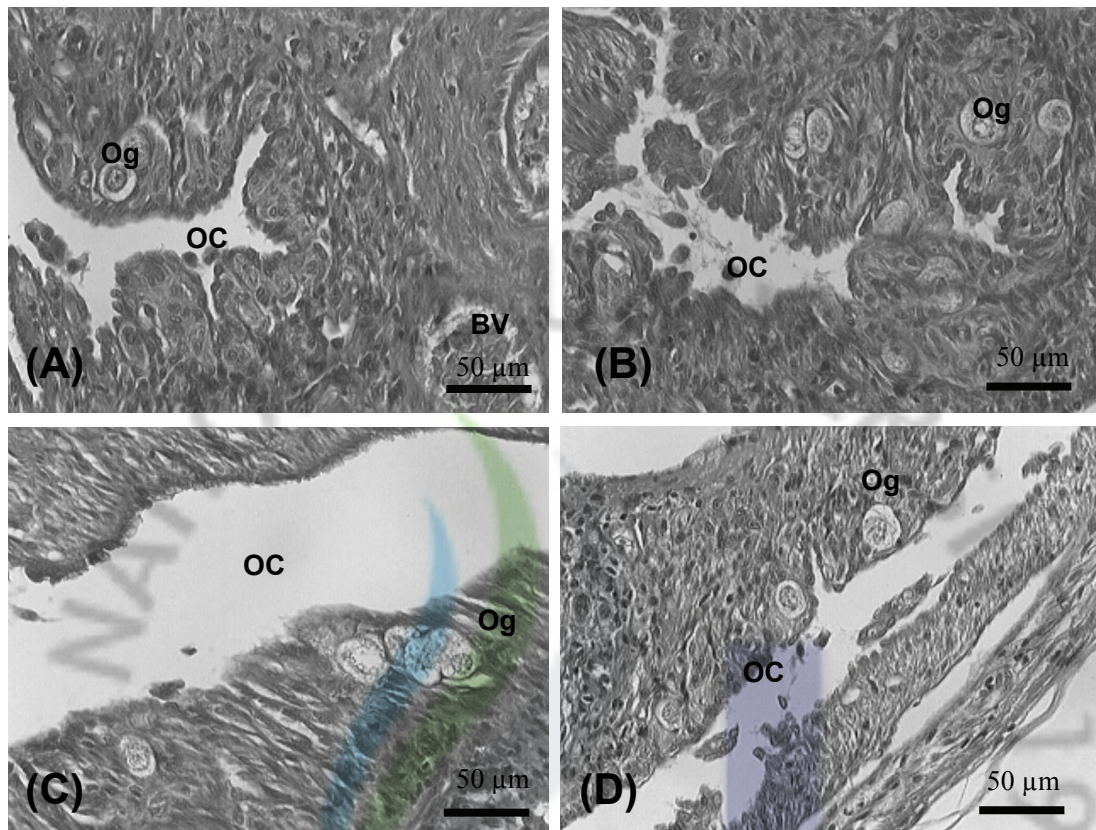


Fig. 10. Gonadal development of control and experimental group after 2 months MT treated (180 DAH). (A) An immature ovary of control fish. (B) Gonad fish of MT1. (C) Gonad fish of an MT2. (D) Gonad fish of an MT3. BV, blood vessel; OC, ovarian cavity; Og, oogonia.

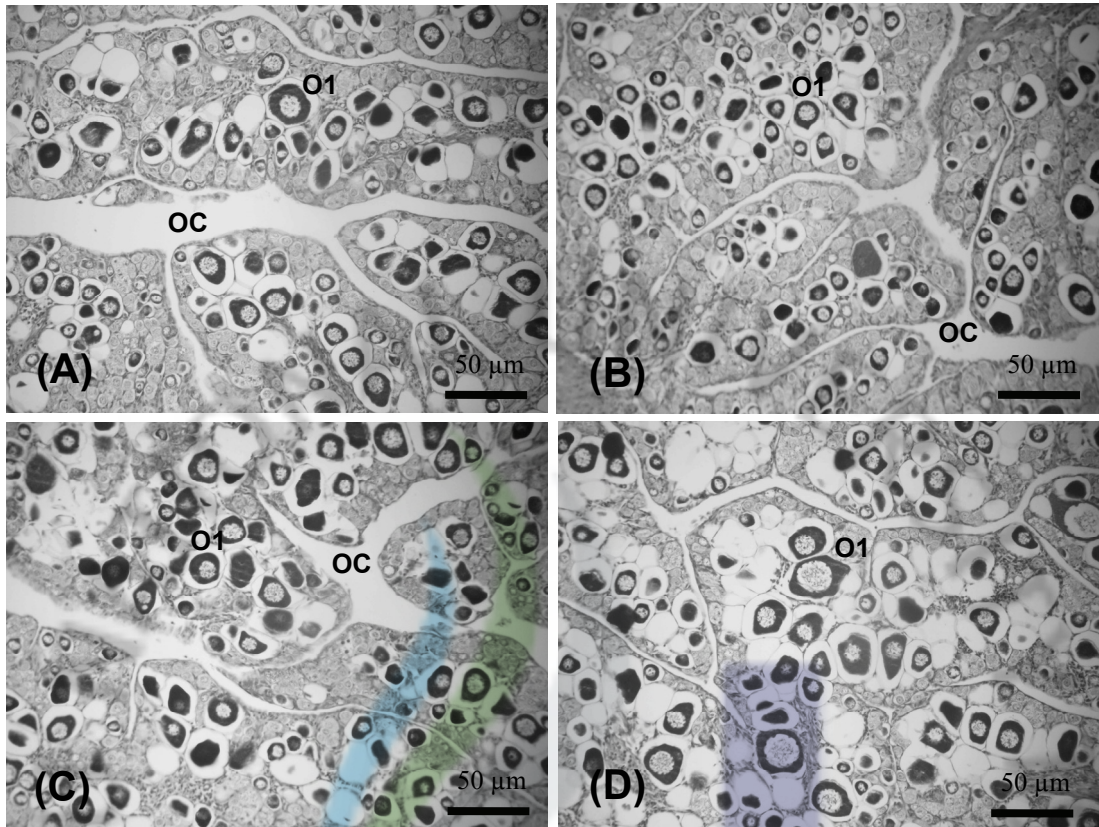


Fig. 11. Gonadal development of control and experimental group after 12 months MT treated (500 DAH). (A) An immature ovary of control fish. (B) Gonad fish of MT1. (C) Gonad fish of MT2 . (D) Gonad fish of an MT3.. BV, blood vessel; OC, ovarian cavity; O1, primary growth stage.

IV. DISCUSSION

Sex differentiation was reported to occur at different post hatching times in most gonochoristic teleost fish (Satoh, 1973; Parmentier, et al., 1985; Braat et al., 1999; Slanchev et al., 2005; Arezo et al., 2007) and protogynous hermaphrodite (Lim, 2000; Devlin and Nagahama, 2002. Murata et al., 2009a). The primordial germ cells (PGCs) arise to the primordial gonad and increase in number through mitosis during specific developmental phase (Parmentier et al., 1985; Braat et al., 1999). In this study, the observation showed that in 10 DAH Longtooth grouper larvae, the primordial germ cells were locate between mesonephric duct and gut (Fig. 2A, B). But, these PGCs were unassociated to other. In 15 DAH larvae (Fig. 2C), the PGCs were associated and increased in number through mitotic. In teleosts fish PGCs could be observed during the embryonic development, shortly after hatching or a few weeks after hatching (Braat et al., 1999). During the period from the hatching in viviparous *Ditrema temmincki*, the PGCs were first observed in the fibrous mesenchymal tissue located between the early alimentary tract and the dorsal body wall (Lee and Lee, 1996). In other case, PGCs could be found at 15 DAH of *Vimba vimba* fish (Hliwa et al., 2003) and *Squalius cephalus* was 35 DAH (Hliwa et al., 2009). In protogynous hermaphrodite Malabar grouper (*E. malabaricus*), PGCs were immigrated in the primordial gonad tissue located below the mesonephric duct at the dorsal side of the intestine at 11 DAH (Murata et al., 2009a). Migration and development of PGCs have been described in several fish species including: carp *Cyprinus carpio* L (Parmentier and Timmermans, 1985), rockfish *Sebastes schlegeli* (Lee et al., 1996), parrot fish *Oplegnathus fasciatus* (Kim, 1998), seabream *Pagrus major* (Lim, 2000), cichlid fish *Cichlasoma dimerus* (Meijide et al., 2005), adriatic

sturgeon *Acipenser naccarii* (Grandi and Chicca, 2008), bluegill sunfish *Lepomis macrochirus* (Gao et al., 2009). Devlin and Nagahama (2002) reported that prior to gonad sex differentiation, all somatic cells appear which was derived from a cortex epithelial layer. In this study, primordial gonads with a few somatic cells were first observed in *Epinephelus bruneus* larvae at 20 DAH (Fig. 2D) and numbers of somatic cells were increased by age of fish. The primordial gonad during early gonad development composed of a few somatic cells was observed at 3 weeks after hatching larvae *Epinephelus coioides* (Liu and Sadovy, 2009). The undifferentiated gonads were consisted of two kinds of somatic cells including the cortex and the medulla. During ovarian differentiation phase, the cortex was developed and the medulla was degenerated (Nakamura et al., 1998). The primordial gonad component germ cells become evident in *Epinephelus bruneus* larvae from 40 to 50 DAH. In Malabar grouper *Epinephenlus malabaricus* the germ cells were first observed in undifferentiated gonad at 39 DAH (Murata et al., 2009a). But Liu and Sadovy (2009) did not identify germ cells in primordial gonad of Orange spotted grouper *Epinephelus coioides* at 7 weeks after hatching. This suggests that the appearance of germ cells in undifferentiated gonad depend upon fish species.

In gonochoristic teleosts fish, the formation of ovarian cavity indicates that the gonad functions as an ovary. The ovarian cavity can take one of several different forms depending different fish species (Nakamura et al., 1998). There are few studies on gonad development during sexual differentiation of protogynous hermaphrodite. In malabar grouper *Epinephenlus malabaricus*, the initial ovarian cavity information were first observed at 47 DAH by appearance two elongations of somatic tissues developed both upward and downward and more developed at 74 DAH. But these

ovarian cavity were not connected to each other. The ovarian cavity formation was accomplished at 144 DAH (Murata et al., 2009a). In orange spotted grouper *Epinephelus coioides* the formation of ovarian cavity were signal of gonadal wall protruded dorsally and ventrally from the area of blood vessels at 26 weeks after hatching, whereas was observed in humpback grouper *Cromileptes altivelis* at 17 weeks after hatching (Liu and Sadovy, 2009). To similar in studied of Liu and Sadovy (2009) and Murata et al. (2009a), in this study showed the initial information of ovarian cavity were first observed at 60 days after hatching (Fig. 5A) with a presence of two elongated aggregations of somatic cells in the gonad and increased side at 90 DAH (Fig. 5B). At 110 DAH (Fig. 5C), the formtion of an ovarian cavity appeared at the central of gonad. To compare with some studied of gonadal development during sexual differentiation in other grouper species have been recently published. This result suggests that in longtooth grouper *Epinephelus bruneus* the ovarian cavity was formed early (110 DAH) than malabar grouper *Epinephenlus malabaricus* (144 DAH), orange spotted grouper *E. coioides* (22 weeks after hatching) and humpback grouper *Cromileptes altivelis* (30 weeks after hatching).

In teleosts fish, ovarian development in female is first detectable with the proliferation of somatic cells and oogonia and early oocyte differentiation (Nakamura et al., 1998; Devlin and Nagahama, 2002). The ovarian ontogeny are varied by germ cell meiosis before or after the formation of the ovarian cavity (Nakamura et al., 1998). For *Vimba vimba* L. 1758, cichlid fish *Cichlasoma dimerus* and fathead minnows *Pemephales promelas* the oogonia were entered meiosis division and appeared of primary stage oocyte perior to the formation of ovarian

cavity (Hliwa et al., 2003; Mejjide et al., 2005; Uguz, 2008). In the contrary, several studies have reported that the meiosis division of oogonia occurs after the formation of the ovarian cavity in gonochoristic parrot fish *Oplegnathus fasciatus*, protogynous hermaphrodite: including seabream *Pagrus major*, malabar grouper *Epinephelus malabaricus*, orange spotted grouper *Epinephelus coioides* and humpback grouper *Cromileptes altivelis* (Lim, 2000; Murata et al., 2009a; Liu and Sadovy, 2009). Like other protogynous hermaphrodite fish species, Longtooth grouper *E. bruneus* appeared to undergo through meiotic division of oogonia and development of primary growth stage oocyte after the formation of ovarian cavity (Fig. 6, 7).

Most grouper species are protogynous hermaphrodite (Shapiro et al., 1993; Sadovy and Colin, 1995; Bhandari et al., 2003; Yeh et al., 2003). Hence, the number of males in the wild and hatcheries are often limited. The induction sex change technique using androgen hormone manipulation is critical for the successes of the breeding programs. But, function male achieved by this way is often temporary with male changing back to female after the termination of androgen treatment (Alam et al., 2007). Alam et al. (2007) reported that the ovarian cavity was remained in the newly formed testis. The most effective masculinization in teleost fish is administration of exogenous steroid hormones during gonadal sexually differentiation (Nakamura et al., 1998). Understanding gonadal development courses during sex differentiation is critical in control sex (Gao et al., 2009). Gonadal development during sex differentiation of Longtooth grouper (*Epinephelus bruneus*), is well described in the present study. This is critical information for establishment of early sex reversal technique in this fish species.

This study were the first attempt on induction of masculinization of juvenile Longtooth grouper during gonadogenesis by MT oral administration at 1 mg, 5 mg and 10 mg kg⁻¹ diet for 30 days fed. After 12 months, no changes were observed in the gonads of MT treated fish. In general, sexually undifferentiated fish are higher sensitive to effects of steroid treatment than sexually differentiated ones (Piferrer, 2001). In this experiment the age of fish were 90 DAH, in which the gonad was differentiated with appearance initial information of ovarian cavity. The calculated quantities of hormone consumed by fish for 30 days period of experiment were 0.5 mg kg⁻¹ body weight for MT1, 2.6 mg MT kg⁻¹ body weight for MT2 and 5.7 mg MT kg⁻¹ body weight for MT3. This suggests that sex differentiation of juvenile longtooth grouper during gonadogenesis was not influenced by MT administration at the doses tested. Several studies (Kuo et al., 1988; Glamuzina et al., 1998; Murata et al., 2009b) reported that induced sex change by MT oral administration in grouper species is required high dose and long time treated. Glamuzina et al. (1998) were successful in masculinization of dusky grouper by oral administration of 113.3 mg MT kg⁻¹ body weight for 4 months treated. Artificial sex change was reported for underyearling *E. malabaricus* when fed a diet with 50 mg MT kg⁻¹ diet for 6 months (Murata et al., 2009b).

V. CONCLUSIONS

The observation in the present study suggest that the primordial germ cells could be observed from 10 to 15 DAH, while undifferentiated gonad occur from 20 to 50 DAH in longtooth grouper (*Epinephelus bruneus*). The initial ovarian phase was 60 to 130 DAH with the formation of ovarian cavity and the increase in size of gonad. The ovarian phase started at 140 DAH with appearance of oogonia. The gonad at 365 DAH appeared to have full of oogonia and primary growth stage oocyte. The observations also indicate that the ovarian differentiation beginning at 60 DAH and that in Longtooth grouper. The gonads differentiated directly into ovaries in all fish examined. MT doses tested in this study may not induce masculinization in juvenile longtooth grouper. High dose of MT may be required for masculinization of this fish. The most effective period for sex reversal using androgen hormone treatment in longtooth grouper (*Epinephelus bruneus*) may be in metamorphosis period at 50 DAH.

VI. REFERENCE

- Alam, M.A & Nakamura, M., 2007. Efferent duct differentiation during female-to-male sexchange in honeycomb grouper *Epinephelus merra*. J. Fish. Biol. 71, 1192–1202.
- Arezo, M.J., D'Alessandro, S., Papa, N., deSá, R., Berois, N., 2007. Sex differentiation pattern in the annual fish *Austrolebias charrua* (Cyprinodontiformes: Rivulidae). J. Tissue and Cell. 39, 89-98.
- Asoh, K. and Yoshikawa, T., 2003. Gonadal development and an indication of functional protogyny in the Indian damselfish, *Dascyllus carneus*. J. Zool. Lond. 260, 23–39.
- Bhandari, R.K., Komuro, H., Nakamura, S., Higa, M. & Nakamura, M., 2003. Gonadal restructuring and correlative steroid hormone profiles during natural sex change in protogynous honeycomb grouper (*Epinephelus merra*). Zoological Science 20, 1399-1404.
- Bhandari, R.K., Higa, M., Nakamura, S. & Nakamura, M., 2004 Aromatase inhibitor induces complete sex change in the protogynous honeycomb grouper (*Epinephelus merra*). Molecular Reproduction and Development. 67, 303-307.
- Braat, A.K., Speksnijder, J. E and Zivkovic, D., 1999. Germ line development in fish. J. Dev. Biolo. 43, 745-760.

- Chen, F.Y., Chow, M., Chao, T.M. & Lim, R., 1977. Artificial spawning and larval rearing of the grouper, *Epinephelus tauvina* (FORSKAL) in Singapore. Singap J. P. Ind. 5, 1-21.
- Donaldson, T.J., Sadovy, Y., Graham, T.R., McGilvray, F., Muldoon, G.J., Phillips, M.J., Rimmer, M.A., Smith, A., Yeeting, B., 2003. While stocks last: the live reef food fish trade. Asian Development Bank. 147pp.
- Devlin, R.H., Nagahama, Y., 2002. Sex determination and sex differentiation in fish: An overview of genetic, physiological, and environmental influences. J. Aquaculture 208, 191-364.
- Gao, Z., Wang, H.P., Rapp, D., Bryant, P.O., Wallat, G., Wang, W., Yao, H., Tiu, L., Donald, R. M., 2009. Gonadal sex differentiation in the bluegill sunfish *Lepomis macrochirus*. Aquaculture 294, 138-146.
- Glamuzina, B., Glavic, N., Skaramuca, B. & Kozul V. (1998) Induced sex reversal of dusky grouper, *Epinephelus marginatus* (Lowe). Aquaculture Research 29, 563-567.
- Grandi, M and Chicca, M., 2008. Histological and ultrastructural investigation of early gonad development and sex differentiation in Adriatic sturgeon (*Acipenser naccarii* Acipenseriformes, Chondrostei). J. Morphology. 269, 1238-1262.
- Hliwa, P., Demska-Zakes. K., Martyniak. A., Król. J., 2003. Gonadal differentiation in *Vimba vimba* (L. 1785). Czech J. Anim. Sci. 48 (11), 441-448.
- Hliwa, P., Zyla, A., Król, J., 2009. Gonadal differentiation in Chub *Squalius (Leuciscus) cephalus* (L. 1758). Flolia biologica (Kraków). 57, 115-120.

- Hoar, W.S., 1969. Sex differentiation. In: Hoar, W.S, Randall, D. J (Eds), Fish physiology, vol. 3. Academic press, New York, 1- 72.
- Hur, S.P. 2008. Masculineization of juvenile longtooth grouper *Epinephelus brueus*. Master Thesis, Cheju National University., Cheju, Korea. 32, 1-39.
- Kim, B.H. 1998. Sex differentiation and gonad development of the parrot fish, *Oplegnathus fasciatus*. Master Thesis, Cheju National University., Cheju, Korea. 32, 6-27.
- Kuo, C.M., Ting, Y.Y. & Yeh, S.L., 1988. Induced sex reversal and spawning of blue-spotted grouper, *Epinephelus fario*. Aquaculture 74, 113-126.
- Kuwamura T, Nakashima Y (1998) New aspects of sex change among reef fishes: recent studies in Japan. Environ Biol Fishes 52:125–135.
- Lahnsteiner, F., Weismann, T., Patzner, R.A., 1997. Structure and function of the ovarian cavity and oviduct and composition of the ovarian fluid in the Bleak, *Alburnus alburnus* (Teleostei, Cyprinidae). J. Tissue and Cell. 29 (3), 305-314.
- Lee, J.S., Lee, Y.D., 1996. Early gonadogenesis and sex differentiation in the viviparous teleost, *Ditrema temmincki*. Bull. Korean Fish. Soc. 29, 34– 43.
- Lee, Y.D., Oh, S.R., Chang, Y.J., Baek, H.J., An, C.M., 1996. Sex differentiation of the rockfish, *Sebastes schlegeli*. J. Korean Fish. Soc. 29, 44-50.
- Lee, Y.D., Song, Y.B., Lim, B.S., Oh, S.R., Kim, H.B., 2008. Grouper aquaculture research in Jeju Island, Korea. In: Bulletin of marine and environmental research institute. 32, 49-60.
- Lee, Y.D., 1995. Sexual phenomenon of protogynous serranid fish. Exploit. Mar. Resour., 143– 150.

- Lee, Y.D., Rho, H.K., Lee, T.Y., 1991. Reproductive ecology of the wrasse, *Halicoeres poecilopterus* (Temminck et Schlegel). Bull. Mar. Res. Inst. Cheju Natl. Univ. 15, 93– 102.
- Li, G.L., Liu, X.C., Lin, H.R., 2007. Seasonal change of serum sex steroids concentration and aromatase activity of gonad and brain in red-spotted grouper (*Epinephelus akaara*). J. Animal reproductive science. 99, 156-166.
- Lim, B.S., 2000. Study on the role of steroid hormone during gonadal sex differentiation in red seabream *Pagrus major*. Thesis, Tokyo University of Marine Science and Technology., Tokyo, Japan. 86, 62-77.
- Liu, M., Sadovy, Y., 2004. Early gonadal development and primary males in the protogynous epinepheline, *Cephalopholis boenak*. J. Fish Biol. 65, 987–1002.
- Liu, M., Sandovy de Mitcheson, Y., 2009. Gonad development during sexual differentiation in hatchery-produced orange-spotted grouper (*Epinephelus coioides*) and humpback grouper (*Cromileptes altivelis*) (Pisces: Serranidae, Epinephelinae) Aquaculture 287, 191-202.
- Meijide, F.J., Lo, N.F.L and Guerrero, G.A., 2005. Gonadal development and sex differentiation in the Cichlid fish *Cichlasoma dimerus* (Teleostei, Perciformes): A light- and electron – microscopic study. Journal of Morphology. 264, 191-210.
- Murata, R., Karimata, H., Alam, M.A., Nakamura, M., 2009a. Gonad sex differentiation in Malabar grouper (*Epinephelus malabaricus*). Aquaculture. 293, 286- 289.

- Murata, R., Karimata, H., Alam, M.A., Nakamura, M., 2009b. Precocious sex change and spermtogenesis in the underyearling Malaber grouper (*Epinephelus malabaricus*) by androgen treatment. J. Aquaculture research. 1-6.
- Nagahama, Y., 1983. The functional morphology of teleost gonads. In: Hoar, W. S, Randall, D. J (Eds), Fish physiology, vol. 9A. Academic press, New York., 223-274.
- Nakamura, M., Kobayashi, T., Chang, X. T and Nagahama, Y., 1998. Gonadal sex differentiation in teleost fish. J. Experimental Zoology. 281, 362-372.
- Oh, S.R., 2006. Seed production of Longtooth grouper, *Epinephelus bruneus* with induced sex reversal and maturation. Doctor Thesis, Cheju National University., Cheju, Korea. 136, 7-40.
- Omoto, N., Maebayashi, M., Mitsuhashi, E., Yoshitomi, K., Adachi, S and Yamauchi, K., 2001. Histological observation of gonadal sex differentiation in the F₂ hybrid sturgeon, the bester. J. Fisheries science. 67, 1104-1110.
- Park, I. S., Kim, J. H., Bang, I. C. and Kim, D.S., 1998. Histological study of the early gonadal development and sexual differentiation in *Rhynchocypris oxycephalus*. J. Development and Reproductive. 2, 69-74.
- Parmentier, H.K and Timmermans, L.P.M., 1985. The differentiation of germ cells and gonads during development of carp (*Cyprinus carpio* L.). A study with anti-carp sperm monoclonal antibodies. J. Embryol. Exp. Morph. 90, 13-32.
- Patiño, R & Redding, J.M., 2000. Reproductive systems. In Ostrander. G. K, The laboratory fish. Academic press, New York. 489-500.
- Piferrer, F., 2001. Endocrine sex control strategies for the feminization of teleost fish. Aquaculture 197, 229-281.

- Sadovy de Mitcheson, Y., Liu, M., 2008. Functional hermaphroditism in teleosts. *Fish and Fisheries*. 9, 1–43.
- Sadovy, Y. & Shaoiro, D.Y., 1987. Criteria for the diagnosis of hermaphrodite in fishes. *Copeia* 1987, 136-156.
- Sadovy, Y., Colin, P.L., 1995. Sex development and sexuality in the Nassau grouper. *J. Fish. Biol.* 46, 961-976.
- Satoh. N., 1972. Sex differentiation of the gonad of fry transplanted into the anterior chamber of the adult eye in the teleost, *Oryzias latipes*. *J. Embryol. Exp. Morph.* 30, 345-358.
- Sarter K., Papadaki M., Zanuy S. & Mylonas C.C., 2006. Permanent sex inversion in 1-year-old juveniles of the protogynous dusky grouper (*Epinephelus marginatus*) using controlled-release 17 α -methyltestosterone implants. *Aquaculture* 256, 443-456.
- Sawada. Y., Kato. K., Okada. T., Kurata. M., Muka.Y., Miyashita. S., Murata. O., Kumai. H., 1999. Growth and morphological development of larval and juvenile *Epinephelus bruneus* (Perciformes: Serranidae). *Ichthyological Research*. 46 (3), 245-257.
- Shapiro, D.Y., Sadovy, Y., McGehee, M.A., 1993. Periodicity of sex change and reproduction in the red hind, *Epinephelus guttatus*, a protogynous grouper. *Bull. Mar. Sci.* 53, 1151-1162.
- Shimizu, M and Takahashi, H., 1980. Process of sex differentiation of the gonad and gonoduct of the three-spined stickleback *Gasterosteus aculeatus* L, *Bulletin of the Faculty of Fisheries Hokkaido University* 31, 137–148.

- Slanchev, K., Stebler, J., Cueva-Méndez, G and Raz., 2005. Development without germ cells: The role of the germ line in zebrafish sex differentiation. J. PNAS. 102 (11), 4074-4079.
- Song, Y.B., 2004. Induction of sexual maturation and early development of the sevenband grouper, *Ephinaphelus septemfasciatus*. Thesis, Cheju National University. Jeju, Korea. 48-50.
- Song, Y.B., Oh, S.R., Seo, J.P., Ji, B.G., Lim, B.S and Lee, Y.D., 2005. Larval development and rearing of Longtooth grouper *Epinephelus bruneus* in Jeju Island, Korea. Journal of the world aquaculture society. 36, 209-216.
- Strüssmann, C.A., Takashima, F. and Toda, K., 1996. Sex differentiation and hormonal feminization in pejerrey, *Odontesthes bonariensis*. Aquaculture 139, 31-45.
- Strüssmann, C.A and Nakamura, M., 2002. Morphology, endocrinology, and environmental modulation of gonadal sex differentiation in teleost fishes. Fish Physiol Biochem. 26, 13-29.
- Strüssmann, C. A and Ito, L. S., 2005. Where does gonadal sex differentiation begin? Gradient of histological sex differentiation in the gonads of Pejerrey, *Odontesthes bonariensis* (Pisces, atherinidae). Journal of Morphology. 265, 190-196.
- Takashima, F and Hibiya, T., 1995. Chapter IX Gonads. An atlas of fish histology. - 2. ed. - Tokyo: Kodansha; Stuttgart; New York: Fischer. 128-153.
- Tan-Fermin, J.D., Garcia, L.M.B., Castillo, A.R., 1994. Induction of sex inversion in juvenile grouper, *Epinephelus suillus*, (Valenciennes) by injection of 17 α -methyltestosterone. Japan. J. Ichthyol. 40, 413-420.

- Uguz, C., 2008. Histological evaluation of gonadal differentiation in fathead minnows (*pimephales promelas*). J. Tissue and Cell. 40, 299-306.
- Yamamoto, T., 1969. Sex differentiation. In: Hoar, W. S, Randall, D. J (Eds), Fish physiology, vol. 3. Academic press., New York, pp. 117-175.
- Yamazaki, F., 1983. Sex control and malipulation in fish. Aqua. 33, 329-354.
- Yeh, S.L., Kuo, C.M., Ting, Y.Y., Chang, C.F., 2003. The effects of exogenous androgens on ovarian development and sex change in female orange-spotted protogynous grouper, *Epinephelus coioides*. J. Aquac. 218, 729-739.



ACKNOWLEDGEMENT

First of all, I would like to express my great gratitude to my supervisor, Prof. Young-Don Lee, Department of Marine Life Science, Jeju National University, South Korea who has always supported me during my study and living in Korea.

I am also thankful to Prof. Kwang- Sik Choi, Prof. Kyeong-Jun Lee, Prof. Saang-Yoon Hyun in Department of Marine Life Science, Jeju National University, for their valuable advices during my study here.

I am very much thankful to Dr. Bong-Soo Lim, Dr. Young-Bo Song, Dr. Chi-Hoon Lee, Dr. Seong-Hoon Kim, Dr. Young-Ju Park and my friends in Marine Development Biology Laboratory for their supporting me in study and doing research. I would like to thank staffs in Marine and Environmental Research Institute, in Jeju National University. I would like to express profound gratitude to Mr Sang-Woo Hur who has always encouraged and helped me. I would like to express the great thank to my friends Mr. Tran Trung Thanh, Mr. Pham Van Hoan, Ms. Nguyen Thi Thanh Khuong, Mr. Le Thanh Cuong, Mr. Nguyen Van Quyen who have encouraged me in study and doing research.

I would like to give special thanks to my brother Pham Minh Anh and his wife Ms Dang Thi Tuyet Mai for their supports.

I would like to express my deep thank to Dr. Pham Anh Tuan, Dr. Le Thanh Luu in Research Institute for Aquaculture No.1, Viet Nam for their advices and encouragements.

Finally, from deepest in my heart, I would like to express special thanks to my grandmother-in-law, my parent, parent-in-law, brothers and sisters for everything

they are doing for me. To my wife and my daughter, I want to say; I love you so much.

