



저작자표시-비영리-변경금지 2.0 대한민국

이용자는 아래의 조건을 따르는 경우에 한하여 자유롭게

- 이 저작물을 복제, 배포, 전송, 전시, 공연 및 방송할 수 있습니다.

다음과 같은 조건을 따라야 합니다:



저작자표시. 귀하는 원저작자를 표시하여야 합니다.



비영리. 귀하는 이 저작물을 영리 목적으로 이용할 수 없습니다.




변경금지. 귀하는 이 저작물을 개작, 변형 또는 가공할 수 없습니다.

- 귀하는, 이 저작물의 재이용이나 배포의 경우, 이 저작물에 적용된 이용허락조건을 명확하게 나타내어야 합니다.
- 저작권자로부터 별도의 허가를 받으면 이러한 조건들은 적용되지 않습니다.

저작권법에 따른 이용자의 권리는 위의 내용에 의하여 영향을 받지 않습니다.

이것은 [이용허락규약\(Legal Code\)](#)을 이해하기 쉽게 요약한 것입니다.

[Disclaimer](#)

The logo of Jeju National University is located in the top left corner. It features a circular emblem with a stylized flame or 'U' shape in the center, surrounded by the text 'JEJU NATIONAL UNIVERSITY 1952'.

석사학위논문

Posterior Position of Disc Decompression Device  
Tip is correlated with Better Treatment Outcome  
in Discogenic Low Back Pain

제주대학교 대학원

의학과

최종우

2012年 2月

Posterior Position of Disc Decompression Device  
Tip is correlated with Better Treatment Outcome  
in Discogenic Low Back Pain

지도교수 최 재 철

최 종 우

이 논문을 의학 석사학위 논문으로 제출함

2012년 2월

최종우의 의학 석사학위 논문으로 인준함

심사위원장	_____	인
위 원	_____	인
위 원	_____	인

제주대학교 대학원

2012년 2월

# ABSTRACT

## Posterior Position of Disc Decompression Device Tip is correlated with Better Treatment Outcome in Discogenic Low Back Pain

최종우

제주대학교 대학원

의학과

**Objective:** The outer portion of Discogenic low back pain is mostly contributable to the abundantly innervated outer annulus. Conventional electrothermal device can not provide sufficient temperature to the outer annulus. The aim of this study is evaluate the correlation between the tip position of the navigable percutaneous disc ablation device named L'DISQ and the treatment outcome during intervertebral disc ablation procedure.

**Method:** Participants consisted of 13 discogenic low back pain patients. Inclusion criteria were symptomatic duration more than 3 months, unresponsiveness to the oral analgesics, physical modalities and spinal interventions, only one level of symptomatic disc with concordant pain resulted from provocation discography, and agreement to the L'DISQ procedure. Patients with radicular pain or zygoapophyseal joint symptom were excluded. During the procedure most posteriorly approached position of the tip of ablating wand is recorded. We evaluate the correlation between the tip position and the treatment outcome.

**Result:** Correlation between the proximity of the wand to the posterior margin of the intervertebral disc and therapeutic outcomes were significant . The correlation coefficient between the distance ratio and improvement of

patients'VAS index was 0.6. Cases in which the ablation tip was contained only in the nucleus showed poor treatment outcome.

**Conclusion:** Discogenic low back pain is thought to be related primarily with outer annulus region of intervertebral disc which has relatively abundant nociceptive nerve endings. During the electrothermal disc decompression procedure as the ablation wand approached more posterior region of the annulus, we could find more preferable clinical outcome of the patients.

# Table of Contents

## I . Introduction

- 1. Limitation of existing spinal intervention methods ..... 1
- 2. Benefits of navigable disc decompressor ..... 2

## II . Method

- 1. Subjects ..... 3
- 2. Provocation discography ..... 4
- 3. Spine intervention using L DISQ ..... 5
- 4. Outcome measure ..... 9

## III. Result

- 1. Patients characteristics ..... 11
- 2. Correlation between the position of the wand and  
therapeutic outcome ..... 13
- 3. Safety outcome ..... 14

## IV. Discussion ..... 15

## V . Conclusion ..... 18

## VI. References ..... 19

## Tables

〈Table 1.〉 Patient characteristics .....	12
〈Table 2.〉 Correlation of tip position ratio and VAS difference .....	13

## Figures

〈Fig. 1.〉 Photograph of the L'DISQnavigable plasma decompression device .....	2
〈Fig. 2.〉 Summary of procedure .....	7
〈Fig. 3.〉 Title of figure .....	8
〈Fig. 4.〉 Distance from the midpoint of the intervertebral disc to the virtual line (A) and distance to the tip of the wand (B) .....	10
〈Fig. 5.〉 Correlation of tip position ratio and VAS difference .....	13

# Posterior Position of Disc Decompression Device Tip is correlated with Better Treatment Outcome in Discogenic Low Back Pain

CHOI JONGWOO

## Introduction

Lumbar discogenic back pain is the functional loss of a disc due to damage by several factors. The external outline of the disc can remain relatively intact without nerve root symptoms.[1] Lumbar discogenic back pain is related to multiple degeneration processes, and is the most common disease of chronic lower back pain, accounting for approximately 45% of all occurrences.[2, 3] Diagnosis can be partly made through physical and imaging findings,[4, 5] however provocation discography provides information about presence and level of symptomatic disc, and is accepted as the current standard for the diagnosis of discogenic pain.[6, 7]

Several treatment options available for discogenic back pain have been developed, ranging from conservative approaches to surgical procedure. Minimal invasive interventions includes Intradiscal electrothermal therapy (IDET) and Nucleoplasty™ (ArthroCare Europe, Stockholm, Sweden); the latter is a method of plasma disc decompression that employs coblation technology. Surgical treatments are spinal fusion and intervertebral artificial disc insertion.

Spinal surgical treatment may be accompanied by significant morbidity and the development of “failed back surgery” syndrome.[8] IDET attempts to shrink intradiscal collagen fibrils and coagulate nociceptive nerve tissue; drawbacks attributed to this technique have been described. Nucleoplasty™ was developed to remove a portion of the nucleus tissue using a one mm-diameter bipolar instrument



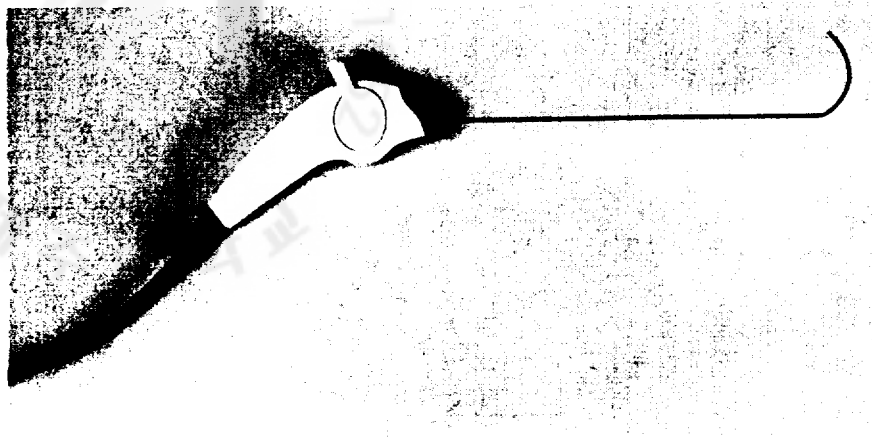
that creates radiofrequency energy that excites the electrolytes in the disc.[8]

Despite some advantages of Nucleoplasty™, the approach is hampered by the use of a rigid and straight wand, which prevents the coblation wand tip from reaching the posterior outer region of intervertebral disc annulus, which is abundant in nociceptive receptors.

Funding from the Korean Health Industry Development Institute (KHIDI) facilitated the development of a navigable plasma decompression device that was designated L'DISQ (U&I, Uijeongbu, Korea) (Fig. 1).[9] The wand can be curved to the desired angles by rotating the control wheel to gain access to the desired site, the posterior torn annulus that is the clinically relevant region in discogenic low back pain. Plasma energy generated at the distal tip of the wand vaporizes a little of nucleus pulposus and ablates the adjacent soft tissues.

The purpose of this study was to evaluate whether the newly developed wand capable of greater posterior advancement improves the clinical outcome during coblation of the disc tissue.

**Fig. 1. Photograph of the L'DISQnavigable plasma decompression device.**



## **METHODS**

### *Subjects*

In a 5-month period after gaining approval from the Korea University institutional review board, written and verbal informed consent was obtained from 16 patients complaining of low back pain. All patients had a 1-month history of axial low back pain unresponsive to conservative management and had obtained a simple plain lumbar X-ray, magnetic resonance imaging (MRI) scan and had undergone an electromyographic study within 3 months before the procedure.

The inclusion criteria were symptomatic duration more than 3 months; unresponsiveness to oral analgesics, physical modalities and spinal interventions; complaint of some limitations of social activities and participation due to the pain; only one level of symptomatic disc with concordant pain resulted from provocation discography; and agreement to the L'DISQ procedure. Exclusion criteria included a radicular pattern of pain, spinal root compression or zygapophyseal arthrosis demonstrated on MRI analysis, electromyographic evidence of lumbosacral radiculopathy or peripheral neuropathy, vertebral fracture demonstrated on plain X-ray analysis, prior surgery at lumbar spine, symptoms or signs of lumbar canal stenosis, psychological issues raised by the examination or history, tumor, systemic infection or localized infection at the anticipated entry needle sites, relation to vehicle accident, a history of coagulopathy, unexplained bleeding, and refusal to participate.

#### *Provocation discography*

Before the disc decompression procedure, provocation discography was performed for all included patients. Antibiotic (1 g of cephalosporin) was administered intravenously about 20 minutes prior to the procedure, and a nonionic contrast medium (Omnipaque 300; GE Healthcare, Milwaukee, WI, USA) was used. Patients were monitored with a two-lead electrocardiogram, continuous pulse oximetry, and blood pressure cuff. Supplemental oxygen was administered by nasal cannula. The discography was performed with a standard posterolateral approach with a 25-gauge spinal needle. The discography needle was connected to the Automated Pressure-Controlled Discography system (APCD system®; Cybermedic Corp., Iksan, Korea). All other procedural details followed the practice guidelines for performing discography, published by International Spine Intervention Society.[10] After the test,

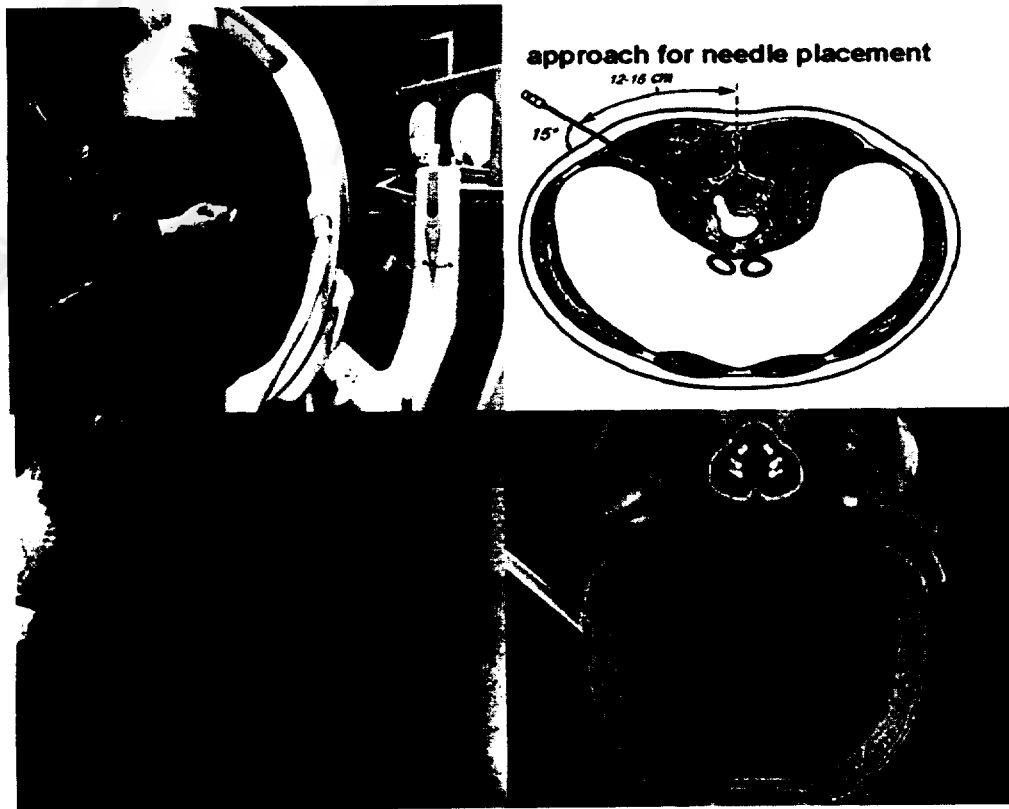
the precise site of torn annulus within symptomatic disc was confirmed by lumbar computed tomography.

### *Spine intervention using LDISQ*


A standard posterior lateral approach to the disc was modified to approach the disc further laterally so that the introducer needle would contact the disc margin at a line drawn between the medial border of adjacent pedicles, rather than the midline.[11] We marked the skin 12–15 cm from the midline to provide the approximate site of needle entry (Fig. 2). The endplates of the target disc space were aligned and the C-arm was rotated ipsilateral to position the lateral margin of the ipsilateral superior articular process approximately three-fifths of the distance across the vertebral body, as visualized in the oblique position. This typically required rotating the C-arm 15 degrees from a zero degree lateral projection. After anesthetizing the skin and subcutaneous fascia to the superior articular process, we manually curved the 16 gauge introducer needle approximately 15 degrees at the distal 1 cm from the distal tip. The introducer needle was directed toward the lateral edge of the superior articular process following the local anesthesia tract and guided by an intermittent fluoroscopic “down the beam” projection using a “corkscrew” rotation of the slightly curved distal tip. Once the lateral edge was touched, we directed the needle tip over the process with the curve pointing away from the midline. Once over the superior articular process, we typically rotated the needle to point toward the midline. Prior to advancing the introducer needle across the midline the anteroposterior (AP) projection was checked. A lateral projection was used to slowly advance the needle across the foramen toward the disc margin. As the needle tip was directed toward the midline, the AP projection was intermittently checked to assure that the needle tip

was always lateral to the medial border of the pedicle. Care was taken not to penetrate the neural tissues and the patient was asked to report any buttock or leg pain.

The advancement of the needle was precisely controlled by rotating the direction of the needle tip bend. Entering the disc was identified by a sudden loss of resistance. After confirming the introducer needle position with the AP and lateral views, the stylet was removed and the wand was advanced through the introducer needle to the torn annulus using fluoroscopic monitoring of the AP and lateral views (Fig. 3). Before ablation, negative motor nerve stimulation confirmed that the needle was not close to the traversing or exiting nerve root. During the ablation, the tip of the wand the tip was continuously rotated and moved back and forward to increase the ablated contact area. The entire procedure was monitored, recorded and evaluated by C-arm fluoroscopy.



**Fig. 2. Summary of the procedure.** The C arm is rotated ipsilaterally as the patient is prone (upper left). The trajectory of the introducer needle (upper right). The tip of the L DISQ wand is located in the posterior annulus of the disc (lower left). The pathway of the wand in the vertebral disc (lower right).



**Fig. 3. Title for figure.** Upper left panel: A post-procedure CT scan. The solid arrow shows the tract made by the plasma decompressor. Top right panel: A fluoroscopy; the white arrow shows the tip of decompressor, which points posterior direction on the AP view. Bottom panel: The black arrow denotes the tip of decompressor on

posterior margin of annulus on a lateral fluoroscopic view


### *Outcome measures*

The baseline values were obtained before the procedure, and patient outcome data were obtained at follow-up visits scheduled at 12 weeks post-procedure. Gathered data were analyzed using a visual analog scale (VAS). The most posterior position of the wand tip during the ablation was recorded. We measured how far the wand approached the posterior margin of the intervertebral disc. We imagined a virtual line on the lateral projection view from the posterior tip of the endplate of the above vertebrae and that of the inferior. The ratio of the distances from the midpoint of the intervertebral disc to the virtual line (A on Fig. 4) and the distance to the tip of the wand (B on Fig. 4) was calculated. For example, if the wand tip was located on the posterior margin of the endplate, the distance from the midpoint of the disc to the virtual line and distance to the wand tip would be identical, and the ratio of the two distances would be 1.

Spearman's correlation coefficient was used to determine statistical significance. We defined post procedure infection, increased intensity of pre-procedure back pain and new-onset neurologic symptom as complications of the procedure. We observed the occurrence of these complications as safety outcome.



**Fig. 4. Distance from the midpoint of the intervertebral disc to the virtual line (A) and distance to the tip of the wand (B).**



## **RESULTS**

### *Patient Characteristics*

Sixteen patients were treated with lumbar disc decompression using L-DISQ. Patients who had coexisting herniated disc that could compress nerve root, or coexisting radicular pain were excluded. Table 1 summarizes patient basic data and the sites of torn annulus on computed tomography.

**Table 1. Patient Characteristics (N=16)**

---

Gender	
Male : Female	12 : 4 (Male, 75.0%)
Age (year)	
Mean±SD	41.63±10.16
Range	20 to 58
Duration of symptoms (months)	
Mean±SD	9.75±8.93
Range	1 to 36
Level of Procedure	
L3/4	2 (12.5%)
L4/5	10 (62.5%)
L5/S1	4 (25.0%)

SD: standard deviation

---

Two patients (12.5% of total), 10 (62.5%) and four (25.0%) were operated on the L3/4 vertebral disc, L4/5 vertebral disc and L5/S1 disc, respectively. When we compared the posterior advancement of the wand tip during the procedure on each vertebral disc level, we found that the ratio of wand tip position and vertebral body width were  $0.50\pm0.28$  on L3/4 disc,  $0.70\pm0.18$  on L4/5 and  $0.62\pm0.37$  on L5/S1 level. The posterior proximity ratio on the L4/5 level was 0.70 and that of L5/S1 was 0.62. The tip of wand could advance more posterior on the L4/5 vertebral disc.

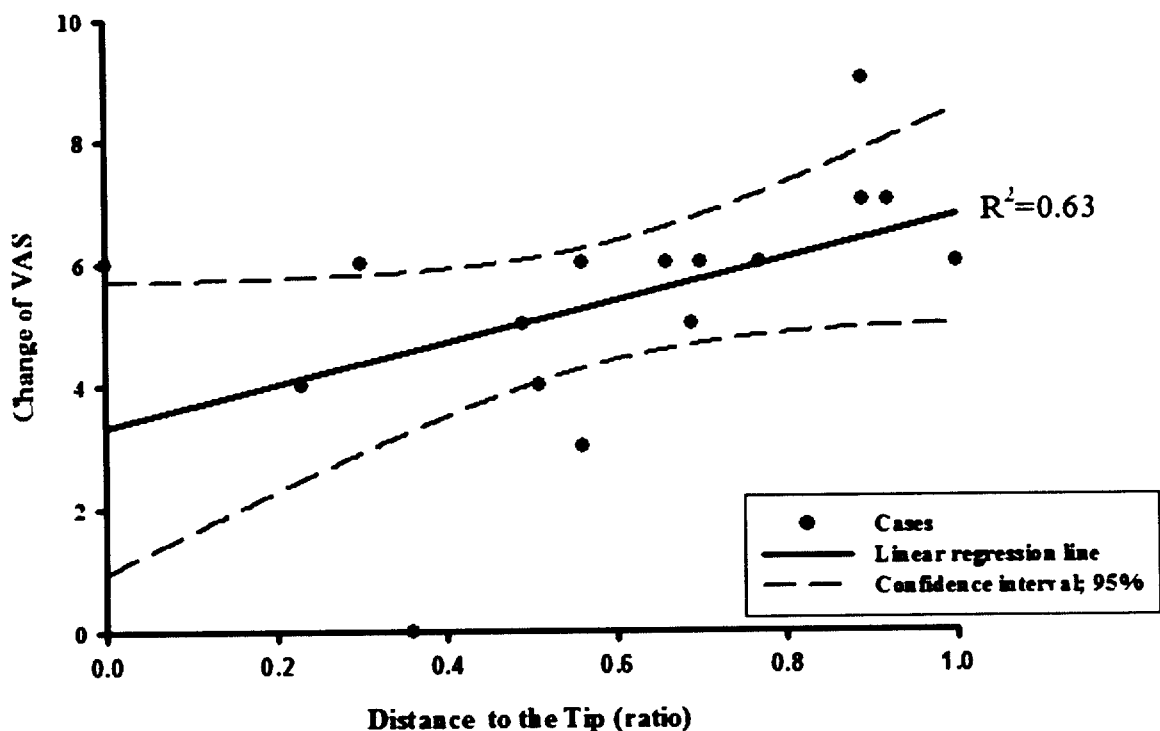
*Correlation between the position of the wand and therapeutic outcome*

Correlation between the proximity how the wand approach posteriorly and therapeutic outcomes were significant (Table 2, Fig. 4). The correlation coefficient between the distance ratio and VAS index was 0.609 ( $P < 0.05$ ).

**Table 2. Correlation of tip position ratio and VAS difference**

		VAS difference
Ratio	Correlation coefficient	0.631
	Probability	0.009

**Fig. 5. Correlation of tip position ratio and VAS difference.**



*Safety outcome*

There was no patient who developed an infection, increased intensity of pre-procedure back pain or new-onset neurologic symptoms.

## Discussion

Presently, as the navigable plasma decompressor wand was increasingly advanced posteriorly, the treatment outcome improved. We used the newly developed L'DISQ navigable decompression device to approach the posterior outer one-third of the annulus fibrosus and tried to overcome the inability of the rigid and straight Nucleoplasty™ system to reach the posterior annular region.

The correlation between the proximity of the wand to the posterior annulus margin and the treatment outcome was analyzed. The presumption was that a more posterior advancement of the ablation wand would produce a better treatment outcome. The posterior annular region is believed to have relatively abundant nociceptive nerve endings. The outer region of the annulus fibrosus is responsible for the discogenic pain, so a more preferable therapeutic outcome should be possible with a sufficient approach to the region during the ablation with the navigable decompression device.

The possible pathologic mechanism of discogenic pain has been suggested to involve disc degeneration caused by biomechanical, biochemical and neural factors acting on pain receptors to produce pain. Repetitive and increased mechanical stress is born unevenly in the burdened disc, and focal stress causes structural damages that are related to a tear or rupture in the annulus fibrosus and vertebral end plate. The painful disc has one or several torn annulus fibrosus, when a tearing portion is extended to the outer one third of the annulus fibrosus, which is correlated with a patient's symptom because of relatively abundant nociceptive nerve endings. The portion of the above torn annulus fibrosus is unevenly loaded by mechanical stress and progresses to a focal inflammatory phase. Also, the symptomatic disc has a significantly higher level of inflammatory cytokines, which stimulate pain receptors

in the outer third of the annulus and end plate.[12, 13] Therefore, this portion of painful disc may be a source of nociceptive stimuli. Moreover, the posterior outer annulus has relatively abundant nociceptive nerve endings. The outer region of the annulus fibrosus is responsible for the discogenic pain, so an increasingly preferable therapeutic outcome is achieved with a sufficient approach to that region during the ablation with the navigable decompression device.

Intradiscal electrothermal annuloplasty was developed in 1998 for discogenic pain using thermal energy. In a human cadaveric study, the histologic findings of thermal effect were confirmed.[14] An attempt was made to shrink the intradiscal collagen fibrils and coagulate nerve tissue using the technique of IDET, in which electrothermal energy is applied to the posterior annular wall through a percutaneous extrapedicular approach using a intradiscal catheter.[15] This minimally invasive disc procedure aims to relieve discogenic back pain while minimizing trauma to normal tissue and enhancing patient recovery. However, despite reports of clinical success in properly selected patients, there have been some drawbacks attributed to this technique. A human cadaveric study that mapped the temperature distribution throughout specimens during the IDET procedure revealed that sufficient thermal dose capable of generating complete thermal damage to the nociceptive nerve fibers infiltrating the disc were limited within 6 mm of the heating probe. Also, only very limited area experience a temperature increase above 60 °C, which is the critical temperature required for coagulation of structural collagen.[16] In an animal study, IDET did not denervate the posterior annular lesion sufficiently.[17] The proposed mechanism of this procedure is the thermal ablation of nociceptive nerve endings at the annulus fibrosus.[15] However, the thermal effect is not enough to ablate the nerve endings of the outer one-third of the annulus fibrosus that is innervated

abundantly as compared to the inner one-third.[16, 18, 19]

Open spine surgery may be considered for cases of discogenic back pain that are intractable to conservative therapy. However, spine surgery may be followed by significant morbidity including the development of postoperative epidural fibrosis and scar formation, disc reherniation, injury to the nerve root, trauma to the cauda equina, vascular complications, the development of “failed back surgery” syndrome, and discitis

Nucleoplasty™ was developed in 2000 and has been approved by the United States Food and Drug Administration.[8] The procedure involves removing a portion of the nucleus tissue using a one mm-diameter bipolar instrument that creates radiofrequency energy that excites the electrolytes in the disc. The energized particles have a sufficient force to break down molecular bonds, which dissolves the soft tissue material of the disc nucleus. Removal of tissue at relatively low temperatures (typically 40°C to 70°C) preserves the integrity of surrounding healthy tissue, therefore reducing the risk of damage to remaining disc tissue and the end-plate cartilage.[8, 20]

In an intact disc, this small volumetric reduction of the nucleus pulposus results in a disproportionate decrease in pressure, thereby relieving some of the chemical and mechanical factors causing pain.[21] Approximately 1 mL of the disc tissue volume is removed, corresponding to a reduction of the discal volume by about 10%–20%. Reduced intradiscal pressure following this procedure has been confirmed in studies on cadaveric specimens, although it has been found that degenerated discs have less pressure reduction than normal discs.[22]



In spite of some advantages of Nucleoplasty™, the rigidity and straight shape of the wand prevents access to the posterior outer region of intervertebral disc annulus, which contains many nociceptive receptors.

Presently, the result L3/4 and L5/S1 intervertebral discs showed more difficulty in approaching the posterior end of the annulus in comparison with the L4/5 disc. We could surmise that the pelvic brim might interfere with the straight approach to the disc, making it difficult to advance to the posterior region of the fibrous annulus.

### **Conclusion**

Discogenic low back pain is thought to be related primarily with outer annulus region of intervertebral disc, which has relatively abundant nociceptive nerve endings.

During the electrothermal disc decompression procedure the ablation wand approached the more posterior region of the annulus. This should produce a more preferable clinical outcome for patients.

## References

1. Zhang, Y.G., et al., *Clinical diagnosis for discogenic low back pain*. International Journal of Biological Sciences, 2009. **5**(7): p. 647-58.
2. Kuslich, S.D., C.L. Ulstrom, and C.J. Michael, *The tissue origin of low back pain and sciatica: a report of pain response to tissue stimulation during operations on the lumbar spine using local anesthesia*. The Orthopedic Clinics of North America, 1991. **22**(2): p. 181-7.
3. Schwarzer, A.C., et al., *The relative contributions of the disc and zygapophyseal joint in chronic low back pain*. Spine, 1994. **19**(7): p. 801-6.
4. Carragee, E.J., et al., *Provocative discography in patients after limited lumbar discectomy: A controlled, randomized study of pain response in symptomatic and asymptomatic subjects*. Spine (Phila Pa 1976), 2000. **25**(23): p. 3065-71.
5. Carragee, E.J., et al., *A gold standard evaluation of the "discogenic pain" diagnosis as determined by provocative discography*. Spine (Phila Pa 1976), 2006. **31**(18): p. 2115-23.
6. Derby, R., et al., *Pressure-controlled lumbar discography in volunteers without low back symptoms*. Pain Medicine, 2005. **6**(3): p. 213-21; discussion 222-4.
7. Wolfer, L.R., et al., *Systematic review of lumbar provocation discography in asymptomatic subjects with a meta-analysis of false-positive rates*. Pain Physician, 2008. **11**(4): p. 513-38.
8. Gerges, F.J., S.R. Lipsitz, and S.S. Nedeljkovic, *A systematic review on the effectiveness of the Nucleoplasty procedure for discogenic pain*. Pain Physician, 2010. **13**(2): p. 117-32.
9. Lee, S.H., et al., *Efficacy of a new navigable percutaneous disc decompression device (L'DISQ) in patients with herniated nucleus pulposus related to radicular pain*. Pain Medicine, 2011. **12**(3): p. 370-6.
10. Society, I.S.I., *Practice Guidelines Spinal Diagnostics and Treatment Procedure*, ed. N. Bogduk 2004: International Spine Intervention Society.
11. Derby R, L.S., Kim BJ., *Discography*. Interventional Spine: an algorithmic approach, ed. D.R. Slipman CW, Simeone FA, Mayer TG 2008: Elsevier.
12. Vanharanta, H., et al., *The relationship of pain provocation to lumbar disc deterioration as seen by CT/discography*. Spine, 1987. **12**(3): p. 295-8.
13. Burke, J.G., et al., *Intervertebral discs which cause low back pain secrete high levels of proinflammatory mediators*. The Journal of Bone and Joint Surgery. British volume, 2002. **84**(2): p. 196-201.
14. Shah, R.V., et al., *Intradiskal electrothermal therapy: a preliminary histologic study*. Archives of Physical Medicine and Rehabilitation, 2001. **82**(9): p. 1230-7.
15. Saal, J.S. and J.A. Saal, *Management of chronic discogenic low back pain with a thermal intradiscal catheter. A preliminary report*. Spine, 2000. **25**(3): p. 382-8.
16. Kleinstueck, F.S., et al., *Temperature and thermal dose distributions during intradiscal electrothermal therapy in the cadaveric lumbar spine*. Spine, 2003. **28**(15): p. 1700-8; discussion 1709.
17. Freeman, B.J., et al., *Does intradiscal electrothermal therapy denervate and repair experimentally induced posterolateral annular tears in an animal model?* Spine, 2003. **28**(23): p. 2602-8.

18. Pauza, K.J., et al., *A randomized, placebo-controlled trial of intradiscal electrothermal therapy for the treatment of discogenic low back pain*. The spine Journal: Official Journal of the North American Spine Society, 2004. **4**(1): p. 27-35.
19. Freeman, B.J., et al., *A randomized, double-blind, controlled trial: intradiscal electrothermal therapy versus placebo for the treatment of chronic discogenic low back pain*. Spine, 2005. **30**(21): p. 2369-77; discussion 2378.
20. Chen, Y.C., et al., *Histologic findings of disc, end plate and neural elements after coblation of nucleus pulposus: an experimental nucleoplasty study*. Spine J, 2003. **3**(6): p. 466-70.
21. Choy, D.S. and P. Altman, *Fall of intradiscal pressure with laser ablation*. Journal of Clinical Laser Medical Surgery, 1995. **13**(3): p. 149-51.
22. Chen, Y.C., S.H. Lee, and D. Chen, *Intradiscal pressure study of percutaneous disc decompression with nucleoplasty in human cadavers*. Spine, 2003. **28**(7): p. 661-5.