

Recurrent angiosarcoma of spleen presented with pancytopenia due to metastasis to bone marrow

Young Ree Kim¹, Woo Kun Kim², Soyoung Hyun², Young-Hee Maeng³

Department of ¹Laboratory Medicine, ²Internal Medicine, ³Pathology, School of Medicine, Jeju National University, Jeju, Korea

Abstract

The patient was a 72 year old male who was referred to Jeju National University Hospital for pancytopenia. Three years prior to this, he visited another hospital for abdominal pain, splenomegaly and thrombocytopenia. His bone marrow was normal at that time. He had an history of hypertension, diabetes, and Parkinson's disease. Laboratory findings showed pancytopenia with leuko-erythroblastic feature. Chest X-ray did not showed a remarkable finding but chest CT scan showed small nodules on bilateral lower lung fields, increased interstitial markings and minimal bilateral pleural effusion. Bone marrow aspiration and biopsy showed tumor infiltration, positively stained for CD34 and negative for common leukocyte antigen, cytokeratin, actin, HMB45, NSE and PSA. Based on the described findings, the diagnosis of angiosarcoma involving the bone marrow was made. Despite treatment with imatinib, he was expired with pulmonary hemorrhage after 3 years from diagnosis. (J Med Life Sci 2009;6:379-382)

Key Words : angiosarcoma, bone marrow, metastasis

Introduction

Angiosarcoma is an uncommon type of soft tissue sarcoma accounting for around 2% of all soft tissue and visceral sarcomas¹⁾. Several different types of angiosarcomas are known including primary angiosarcoma of scalp, angiosarcoma associated with lymphedema, primary breast angiosarcoma, angiosarcoma arising in irradiated fields and vinyl chloride induced liver angiosarcoma²⁾ Primary splenic angiosarcoma is very rare, even more its metastasis to bone marrow without systemic spread is extremely unusual. On this occasion, the prognosis is very poor and there is no established standard treatment in metastatic angiosarcoma. We present a rare case with primary splenic angiosarcoma who presented with pancytopenia due to metastasis to bone marrow.

Case Report

The patient was a 72 years old male who was referred to Jeju National University Hospital for pancytopenia. Three years prior to this, he visited another hospital for abdominal pain, splenomegaly and thrombocytopenia.

He had an history of hypertension, diabetes, and Parkinson's disease. The spleen was invaded by sarcomatous lesions without other organ metastasis and pathologic findings showed positive for CD31 and CD34. There was no remarkable finding in bone marrow aspiration and biopsy. The diagnosis of primary splenic angiosarcoma was made. After splenectomy, abdominal pain and thrombocytopenia were resolved. He did well thereafter without any additional treatment until several months prior to the referral to Jeju National University Hospital.

On examination, no particular abnormalities were found besides being pale and having slightly high blood pressure, 150/90 mmHg. No petechiae or ecchymosis were noticed. Laboratory findings showed hemoglobin 7.9 g%, WBC 2,900 /uL with normal differential counts and platelet counts 26,000 /uL. Mean Corpuscular Volume was 104.2 fL and uncorrected reticulocyte count was 7.23%. Peripheral blood smear revealed leuko-erythroblastic feature. Prothrombin time and activated Partial Thromboplastin Time were normal.

Folic acid and vitamin B12 level were normal. Blood chemistries were not remarkable except minimally increased LDH 682 (normal 180-460 IU/L). Bilirubin, BUN, creatinine, and transaminases were normal. Urinalysis showed no abnormality. Tumor markers such as CEA, CA 19-9, PSA were all normal.

Chest X-ray did not showed a remarkable finding but chest CT scan showed small nodules on bilateral lower lung

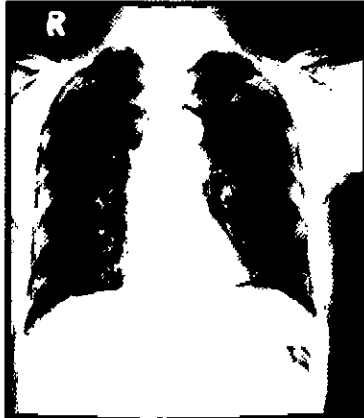Address for correspondence : Young Ree Kim
Department of Laboratory Medicine, Jeju National University School of Medicine, 66 Jejudaehakno, 690-756, Jeju, Korea
E-mail : namu8790@jejunu.ac.kr

fields, increased interstitial markings and minimal bilateral pleural effusion (Fig. 1). These findings were presumed to be metastasis from splenic angiosarcoma. Bone marrow aspiration and biopsy showed tumor infiltration. The tumor cells were positively stained for CD 34 and negative for common leukocyte antigen (Fig. 2). Other stains including cytokeratin, actin, HMB45, NSE and PSA were all negative. These findings were interpreted as angiosarcoma involving the bone marrow. No other organ metastasis was found. His hematological picture was interpreted to be from bone marrow involvement by angiosarcoma. Although there is no established standard regimen of metastatic angiosarcoma, we tried to find new regimen that would not cause further marrow suppression. All things considered, treatment with imatinib was started.

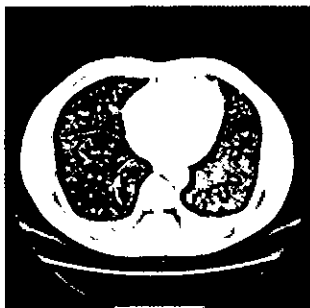
However, the hospital course was complicated with rapidly developing severe frank hemoptysis, hypoxia and exacerbation of anemia and thrombocytopenia. Chest X-ray showed increased ground glass opacities in both lungs and HRCT scan of chest became much worse consistent with

Figure 1. A, B, C

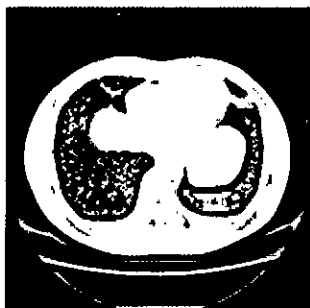Chest X-ray was not remarkable, but HRCT scan of chest showed small nodules on bilateral lower lung fields and increased interstitial markings as well as minimal bilateral pleural effusion.



A. Chest X-ray



B. Chest-CT




C. Chest-CT

pulmonary hemorrhage (Fig. 3). He required multiple transfusions both red cells and platelet. High dose steroid and tranexamic acid were given under the impression that he had diffuse alveolar hemorrhage. Despite treatment with imatinib, he was expired with pulmonary hemorrhage after 3 years from diagnosis(Fig. 3).

Figure 2. A, B, C, D

Bone marrow aspiration smear and biopsy showed tumor infiltration. The tumor cells were positively stained for CD 34 and negative for common leukocyte antigen.




A. Wright-Gimsa stain (x100)



B. Wright-Gimsa stain (x400).



C. Leukocyte common antigen stain(x100)



D. Leukocyte common antigen stain(x400)

Discussion

Primary splenic angiosarcoma is a very rare and aggressive neoplasm with a high metastatic rate and dismal prognosis. A retrospective review of 161 cases with angiosarcoma showed that only 7 patient (4%) had splenic involvement as primary site and the most common metastatic sites were lung(25%), bone (22%), liver (16%), brain (11%) followed by lymph nodes and skin.


Eleven percent of metastasis were comprised of other sites the details of which were not described³.

They usually present with splenomegaly and majority of them have abnormal hematologic findings such as anemia and thrombocytopenia^{4, 5} as our patient did with splenomegaly and thrombocytopenia.

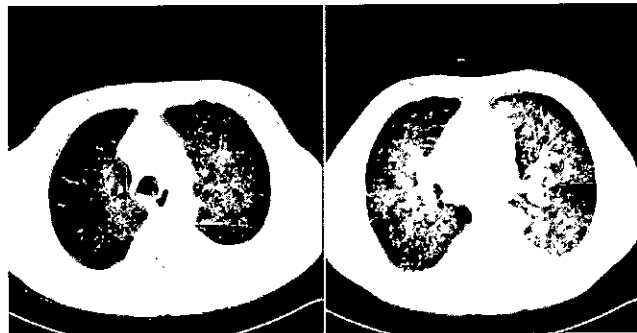Immunophenotypic studies of primary splenic angiosarcoma were well described by Neuhauser and et al.⁵. Twenty-one of 25 cases (84%) were positive for two or more markers of vascular differentiation (CD31, CD34, and FVIIIIRAg). Our patient had CD31 and CD34 positive on the splenectomy

Figure 3. A, B, C

Chest X-ray showed increased ground glass opacities in both lungs and HRCT scan of chest became much worse consistent with pulmonary hemorrhage,



A. Chest X-ray



B. Chest-HRCT

C. Chest-HRCT

specimen when he was diagnosed. Unfortunately, we could not do CD31 staining on bone marrow at the time of recurrence but the tumor cells in bone marrow were CD34 positive and leukocyte common antigen negative. These findings and the general morphology were consistent with original angiosarcoma which metastasized to the bone marrow.

Neuhauser and et al.⁵ described all of their 28 patients' clinical courses and metastatic sites in detail. The majority of the metastases developed to multiple organs such as liver, lung, bone, and lymph nodes. Among 28, 6 patients were reported as having wide metastasis and thus it is difficult whether any of them had bone marrow metastasis, however, no isolated bone marrow metastasis was described. Hsu and et al. reported only 6 cases of primary splenic angiosarcoma collected from 1991 through 2004, among which one patient had metastasis to the bone marrow and to the liver at the time of initial diagnosis and another patient developed metastasis to the bone marrow and to the liver later on. Again, no isolated bone marrow metastasis was found⁶.

Our patient's main problem was pancytopenia which turned out to be from the metastasis to bone marrow. In view of occasional blood tinged sputum for several months, it is possible that he could have had lung metastasis as well, however radiologically, it was not quite evident till close to his final days.

Primary splenic angiosarcomas are very aggressive neoplasms with very poor survival rates as was in our patient. Neuhauser et al.⁵ reported follow up information on 27 out of the total 28 patients. Excluding 2 patients who did survive 8-10 years, the remaining 25 patients died with disseminated tumors (mean, 11 mo; median, 5 mo) within 29 months from initial diagnosis, irrespective of the type of treatment rendered. Hsu et al. reported median survival 23.5 months on their patients⁶. The only other large study by Falk et al. which included the follow-up for 38 out of their total 40 patients revealed that 30 (79%) died at a median interval of 6 months (range 0-48 months) and 8 were alive 5-21 months after diagnosis⁷.

There is no known standard treatment in metastatic angiosarcoma. Weekly paclitaxel seems to have some activity on angiosarcoma, however, there was no difference in progression free survival regardless of treatment⁸. Thus, our patient was given the option of imatinib. Imatinib was reported to have good result on aggressive fibromatosis⁹. Interestingly, a case report was published that imatinib gave a striking and durable response in a patient of

angiosarcoma whose tumor was negative for GIST- type KIT and PDGFR10. Unfortunately, our patient deteriorated rapidly during the last 2 weeks of his life and the trial of imatinib was too short to evaluate the efficacy.

References

- 1) Coindre JM, Terrier P, Guillou L, Le Doussal V, Collin F, Ranchère D, et al: Predictive value of grade for metastasis development in the main histologic types of adult soft tissue sarcomas: A study of 1240 from the French Federation of Cancer Centers Sarcoma Group. *Cancer* 2001;91:1914-26.
- 2) DePinho RA, Weinberg RA. Sarcoma of the soft tissue and bone. In: Devita BT, Lawrence TS, Rosenberg SA, editors. : Devita, Hellman, and Rosenberg's Cancer: Principles and Practice of Oncology. 8th ed. Lippincott Williams and Wilkins, 2008 :1883-4.
- 3) Fayette J, Martin E, Piperno-Neumann S, Le Cesne A, Robert C, Bonvalot S, et al. Angiosarcomas, a heterogeneous group of sarcomas with specific behavior depending on primary site: A retrospective study of 161 cases. *Annals of Oncology* 2001;91:1914-26.
- 4) Falk S, Krishnan J, Meis JM. Primary angiosarcoma of the spleen: A clinicopathologic study of 40 cases. *Am J Surg Pathol* 1993;17:959-70.
- 5) Neuhauser TS, Derringer GA, Thompson LD, Fanburg-Smith JC, Miettinen M, Saaristo A, et al. Splenic angiosarcoma: A clinicopathologic and immunophenotypic study of 28 cases. *Mod Pathol* 2000;13:978-87.
- 6) Hsu JT, Chen HM, Lin CY, Yeh CN, Hwang TL, Jan YY, et al. Primary Angiosarcoma of the Spleen. *J Surg Oncol* 2005;92:312-6.
- 7) Falk S, Krishnan J, Meis JM. Primary angiosarcoma of the spleen: A clinicopathologic study of 40 cases. *Am J Surg Pathol* 1993;17:959-70.
- 8) Penel N, Bui BN, Bay JO, Cupissol D, Ray-Coquard I, Piperno-Neumann S, et al. Phase II Trial of Weekly Paclitaxel for Unresectable Angiosarcoma: The ANGIOTAX Study. *J Clin Oncol* 2008;26:5269-74.
- 9) Heinrich MC, McArthur GA, Demetri GD, Joensuu H, Bono P, Herrmann R, et al. Clinical and molecular studies of the effect of Imatinib on advanced fibromatosis. *J Clin Oncol* 2006;24(7):1195-1203.
- 10) Kiesel H, Mueller AM, Schmitt-graef A, Veelken H. Dramatic and durable efficacy of imatinib in an advanced angiosarcoma without detectable KIT and PDGFRA mutations. *Cancer Biol Ther.* 2009 Feb;8(4):319-21.