

Second case of human infection with *Mesocestoides lineatus* in Korea

Keeseon S. Eom, Seung-Ho Kim* and Han-Jong Rim**

Department of Parasitology, College of Medicine, Chungbuk National

*University, Cheongju 360-763, Department of Veterinary Science,**

College of Agriculture, Cheju University, Department of

*Parasitology,** College of Medicine, Korea University,*

Seoul 136-705, Korea

Abstract: The second case of human infection with *Mesocestoides lineatus* in Korea was reported. The patient, a farm worker, complained of abdominal pain and massive discharge of sesame-like proglottids in his stool for several months. Worms, recovered by chemotherapy with niclosamide, consisted of 32 strobilae. This may be the heaviest worm burden in human infection ever reported. The infected man habitually ate the raw viscera of chickens.

Key words: *Mesocestoides lineatus*, cestoda, human infection, Korea

INTRODUCTION

Mesocestoides lineatus Goeze, 1782 is a rare cestode infecting man. Fourteen cases of human infections have been reported in Japan (Kosaka, 1942; Nagase *et al.*, 1983), one in Korea by Choi *et al.* (1967) and one in China by Fan (1988). Another species, *Mesocestoides variabilis* Mueller, 1927 is also known to have caused human infections in U.S.A., Africa and Denmark (Chandler, 1942; Hutchison and Martin, 1980). The life cycle of the genus *Mesocestoides* is not completely known yet, but the human infection sources are considered to be snakes, birds and small mammals (Beaver *et al.*, 1984). In Korea, very little information is available on this cestode. In addition to the first report of human infection (Choi *et al.*, 1967), Kobayashi (1928) recorded *Mesocestoides* infection in dogs in Seoul. Cho *et al.* (1982) first described natural tetrathyridial infection in a snake, *Elaphe rufodorsata* collected in Kangwon Do.

In this report, we describe another case of human infection by *M. lineatus* in this country.

CASE REPORT

A 45-year-old poultry farm worker, living in Deokcheon-Ri, Kujwa-Eup, Cheju-do, Korea, complained of intermittent abdominal pain, hunger pain and dizziness for several months. In addition, he found many, small, sesame-like worms almost daily in his stool. He had no history of overseas travel. He was treated with 2 g of niclosamide. He admitted that he habitually ate the raw viscera of chickens.

WORM DESCRIPTION

A total of 32 worms, without scoleces, were recovered measuring up to 71 cm in body length and 2 mm in width after formalin fixation (Fig. 1 and 2). Individual free gravid proglottids ranged from 2.10 to 2.25 mm in length and from 1.25 to 1.43 mm in width with a paruterine organ

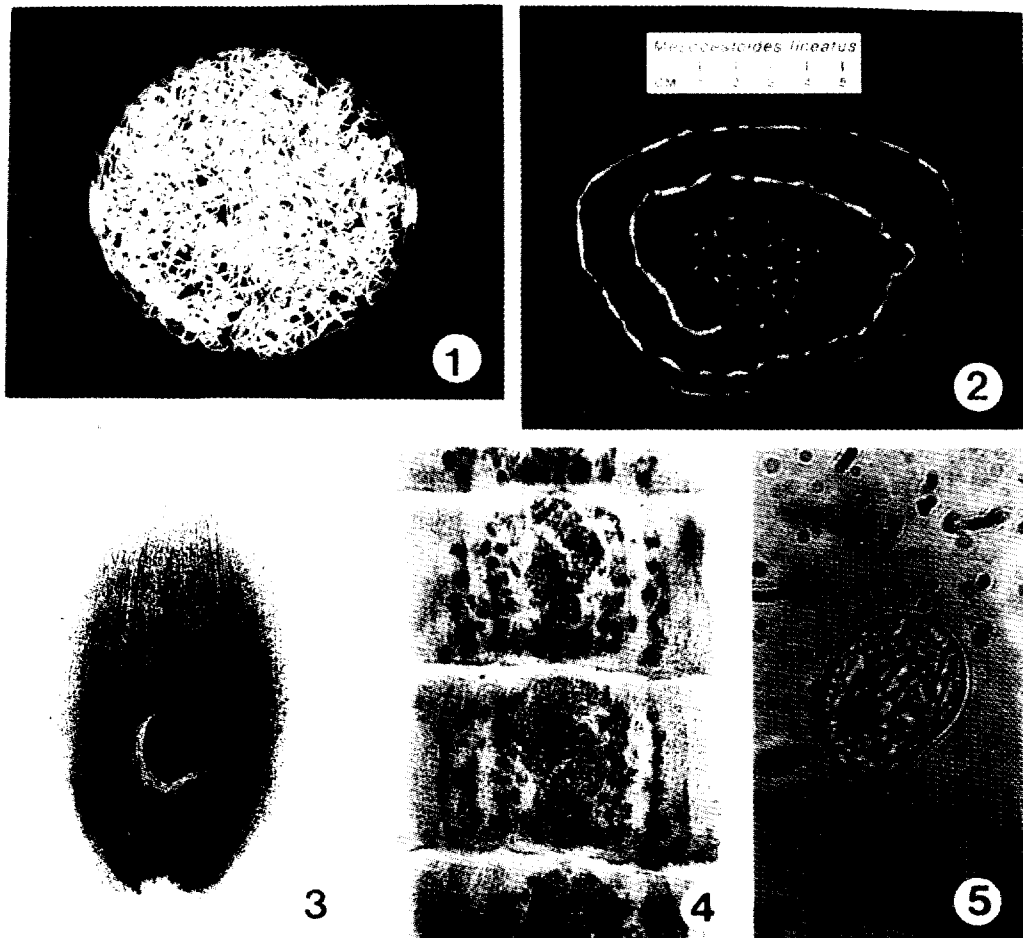


Fig. 1. Multiple *Mesocestoides lineatus* infection, 32 worms were recovered.
Fig. 2. A whole strobila with free gravid proglottids.
Fig. 3. A gravid proglottid with a paruterine organ(Semichon's acetocarmine stained, $\times 25$).
Fig. 4. Mature proglottids(Semichon's acetocarmine stained, $\times 30$).
Fig. 5. Egg containing hexacanth embryo($\times 100$).

measuring 0.50~0.58 mm by 0.50~0.53 mm (Fig. 3). Mature proglottids measured 0.75 to 1.08 mm by 1.10~1.50 mm (Fig. 4). The paruterine organ was located posterior to the uterus on the midline and measured 0.25~0.28 mm by 0.24~0.25 mm in diameter. Ovaries bilobed and posterior, measured 80~130 μm in length. Testes pre- or postovarian, 42 to 54 in number, measured 35~89 by 30~68 μm . Cirrus oval, preequatorial, measured 120 to 170 μm by 75 to 100 μm . Oval eggs measuring 28.2~31.7 μm by 20.1~24.1 μm contained hexacanth embryo(Fig. 5).

DISCUSSION

Due to its unique morphology and the life cycle, the family Mesocestoididae(Perrier, 1897) is a poorly understood cestode group. In subfamily Mesocestoidinae(Perrier, 1897), there is only one genus *Mesocestoides*(Vaillant, 1863) which is unique in having paruterine organ as a diagnostic key. Schmidt(1986) considered that many species of this genus may actually be synonyms distributed in various geographic areas and hosts. Some classifications by different authors such as Witenberg(1934), Wardle and McLeod(1952),

Table 1. Comparison of reported measurement data on *Mesocestoides lineatus* of human cases by different authors

	Kamegai <i>et al.</i> (1967)	Choi <i>et al.</i> (1967)	Present authors
Scolex(mm)	0.56	0.48×0.34	(—)
Strobilae(cm)	up to 75	47~136	up to 71
Paruterine organ(μm)	465~600×468~735	374	450~590×410~550
Testes number	41~60	(—)	42~54
size(μm)	38	(—)	35~89×30~68
Cirrus sac(μm)	162~253×116~209	(—)	120~170×75~100
Eggs(μm)	31~34×24~29	31~34×24~27	28~32×20~24

Voge(1955), Wardle *et al.* (1974) are now available. Eut in East Asia, the cestode is classified as *Mesocestoides lineatus* as in the reports of Japanese cases.

Mesocestoides lineatus was found in dogs by Goetze in 1782, and has been frequently reported from carnivores thereafter. So far, the first intermediate host, presumably insects, has not been found. But the tetrathyridium, a larval form which is readily infective to predatory definitive hosts, has been observed in 20 species of mammals, 15 species of avians and 22 species of reptiles(Witenberg, 1934). As for snake hosts, Kumata *et al.* (1972) found tetrathyridia from *Agkistrodon halys* in Japan and Cho *et al.* (1982) from *Elaphe rufodorsata* in Korea.

Many reports in Japan suggest snakes, such as *Elaphe quadrivirgata*, *Agkistrodon halys*, as infection sources of this worm because of the custom of eating raw snakes for medicinal purposes (Kosaka, 1942; Ito *et al.*, 1962; Hagihara *et al.*, 1964; Tanaka *et al.*, 1967; Kamegai *et al.*, 1967; Kumata *et al.*, 1972; Kagei *et al.*, 1974; Morisita *et al.*, 1975). In Korea *Agkistrodon blomhoffi brevicauda*, a viper, was reported as an infection source of this cestode(Choi *et al.*, 1967). In the present case, however, the patient admitted that he used to eat the raw viscera of chickens. Most of the seven human cases reported in regions outside East Asia, however, the infection source was uncertain except for the case of Fain and Herin(1954) for whom the partridge was regarded as a possible source of infection. In that locality, tetrathyridia had been observed in chickens, guinea hens and

partridges.

In the first Korean case of mesocestoidiasis, the worm was identified as *Mesocestoides* sp. As shown in Table 1, we could not find any morphologic difference between that worm and those of our study. Therefore, the worms collected from the first case were also thought to be *M. lineatus*.

ACKNOWLEDGEMENT

The authors thank Prof. Seung-Yull Cho, Department of Parasitology, College of Medicine, Chung-Ang University for providing many references and valuable discussions.

REFERENCES

- Beaver, P.C., Jung, R.C. and Cupp, E.W. (1984) Clinical parasitology. 9th Ed., pp.825, Lea & Febiger, Philadelphia.
- Chandler, A.C. (1942) First record of a case of human infection with tapeworms of the genus *Mesocestoides*. *Am. J. Trop. Med.*, 22:493-496.
- Cho, S.Y., Song, K.W. and Lee, S.H. (1982) Cestode parasites of terrestrial snakes in Korea. *Chung-Ang J. Med.*, 7(4):321-332 (in Korean).
- Choi, W.Y., Kim, B.C. and Choi, H.S. (1967) The first case of human infection with tapeworms of the genus *Mesocestoides* in Korea. *Korean J. Parasit.*, 5(2):21-25 (in Korean).
- Fain, A. and Herin, V. (1954) Notes a propos d'un cas d'infestation humaine par un *Mesocestoide* a Astrida (Ruanda-Urundi). *Ann. Soc. Belge Med. Trop.*, 34:893-900.
- Fan, S.Q. (1988) First case of *Mesocestoides lineatus*

- infection in China. *Chinese J. Parasitol. and Parasitic Dis.*, 6(4):310.
- Hagihara, T., Amaki, K., Okayasa, D., Nakashima, S., Iwata, A., Higo, T., Sugihara, K., Chata, N. and Kono, K. (1964) Two cases of curious helminthiasis (*Mesocestoidiasis* and *Mansoniasis*). *Jpn. Med. J.*, 2083:24-27 (in Japanese).
- Hutchison, W.F. and Martin, J.B. (1980) *Mesocestoides* (Cestoda) in a child in Mississippi treated with Paromomycin sulfate (Humatin®). *Am. J. Trop. Med. Hyg.*, 29(3):478-479.
- Ito, J., Honda, J. and Ishiguro, M. (1962) The second record of a case of human infection with *Mesocestoides lineatus* in Japan (Cestoda). *Jpn. J. Parasitol.*, 11(2):5-9 (in Japanese).
- Kagei, N., Kihata, M., Shimizu, S., Urabe, M. and Ishii, A. (1974) The 10th case of human infection with *Mesocestoides lineatus* (Cestoda: Cyclophyllidea) in Japan. *Jpn. J. Parasitol.*, 23(6):376-382 (in Japanese).
- Kamegai, S., Ichihara, A., Nonobe, H. and Machida, M. (1967) The 6th and 7th records of human infection with *Mesocestoides lineatus* (Cestoda) in Japan. *Res. Bull. Meguro Parasit. Mus.*, 1:1-7.
- Kobayashi, H. (1928) On the animal parasites in Chosen (Korea). Second report. *Acta Med. Keijo*, 11:109-124.
- Kosaka, S. (1942) The first record of human infection with *Mesocestoides lineatus* in Japan. *Jikken Shokakibyogaku Zasshi*, 17:405-408 (in Japanese).
- Kumata, N., Mizuno, S., Kato, Y., Mizuno, T., Oya, H., Suzuki, T. and Hattori, T. (1972) Eighth record of a human case of *Mesocestoides lineatus* (Cestoda: Cyclophyllidea) in Japan. *Jpn. J. Parasitol.*, 21(5):336-345 (in Japanese).
- Morisita, T., Nagase, K., Moriyama, K. and Matsumoto, Y. (1975) The 11th case of human infection with *Mesocestoides lineatus* in Japan. *Jpn. J. Parasitol.*, 24(6):353-356 (in Japanese).
- Nagase, K., Kani, A., Totani, T., Hamamoto, T. and Torikai, K. (1983) Report of a human case of *Mesocestoides lineatus* and preliminary investigation into infective sources. *Jpn. J. Parasitol.*, 32(Suppl.):18 (abstract in Japanese).
- Schmidt, G.D. (1986) CRC Handbook of tapeworm identification. pp. 675, CRC Press, Inc.
- Tanaka, H., Miyamoto, K., Kancko, K., Czu, S. and Aida, C. (1967) A human case of *Mesocestoides lineatus*. *Jpn. J. Parasitol.*, 16(5):369-374 (in Japanese).
- Voge, M. (1955) North American cestodes of the genus *Mesocestoides*. *University of California Publication in Zoology*, 59(5):125-156.
- Wardle, R.A. and McLeod, J.A. (1952) The zoology of tapeworms. University of Minnesota Press, Minneapolis.
- Wardle, R.A., McLeod, J.A. and Radinovsky, S. (1974) Advances in zoology of tapeworms, 1950~1970. University of Minnesota Press, Minneapolis.
- Witenberg, G. (1934) Studies on the cestode genus *Mesocestoides*. *Arch. Zool. Ital.*, 20:467-509.

=국문초록=

有線條蟲의 國內 人體寄生 第 2 例

忠北大學校 醫科大學 寄生蟲學教室¹⁾, 濟州大學校 農科大學 獸醫學科²⁾

高麗大學校 醫科大學 寄生蟲學教室³⁾

嚴基善¹⁾ · 金承浩²⁾ · 林漢鍾³⁾

한국에서의 有線條蟲(*Mesocestoides lineatus*)에 의한 두번째 인체기생례를 보고하였다. 함께 같은 이물질을 대변 내에 배출하고 수개월 동안 간헐적인 복통을 호소한 45세 남자를 치료한 후 최수한 증체는 모두 32마리 이었다. 카민 염색한 성숙편질 및 수태편질에서 관찰되는 부자궁(paruterine organ)과 충란의 특징적인 형태로 본 종을 동정할 수 있었다. 감염자는 양계장에 근무하면서 닭의 내장을 많이 생식하였다고 하였다.